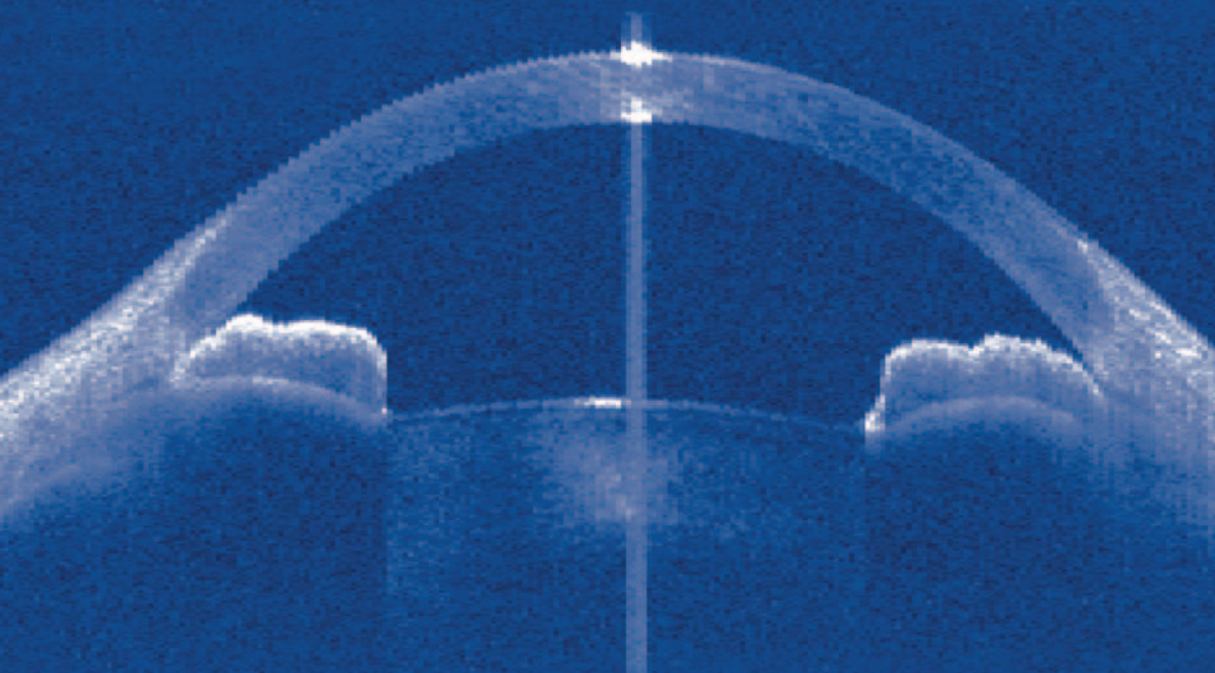




Kugler Publications, The Hague, The Netherlands

# **Angle Closure and Angle Closure Glaucoma**



Robert N. Weinreb and David S. Friedman

Consensus Series - 3

# ANGLE CLOSURE AND ANGLE CLOSURE GLAUCOMA



# **ANGLE CLOSURE AND ANGLE CLOSURE GLAUCOMA**

**Reports and Consensus Statements of the  
3rd Global AIGS Consensus Meeting on  
Angle Closure Glaucoma**

edited by

Robert N. Weinreb  
and  
David S. Friedman



**Kugler Publications/The Hague/The Netherlands**

ISBN 10: 90-6299-210-2  
ISBN 13: 978-90-6299-210-2

Distributors:

For the USA and Canada:  
Pathway Book Service  
4 White Brook Road  
Gilsum, NH 03448  
U.S.A.  
email: [pbs@pathwaybook.com](mailto:pbs@pathwaybook.com)

For all other countries:  
Kugler Publications  
P.O. Box 97747  
2509 GC The Hague, The Netherlands  
Telefax (+31.70) 3300254

**website: [www.kuglerpublications.com](http://www.kuglerpublications.com)**

© Copyright 2006 Kugler Publications

All rights reserved. No part of this book may be translated or reproduced in any form by print, photoprint, microfilm, or any other means without prior written permission of the publisher.  
Kugler Publications is an imprint of SPB Academic Publishing bv, P.O. Box 97747  
2509 GC The Hague, The Netherlands

**This publication is the third  
of a series on  
Consensus meetings in Glaucoma  
under the auspices of the  
Association of  
International Glaucoma Societies**



Angle Closure and Angle Closure Glaucoma Consensus Meeting Participants. Fort Lauderdale, May 3, 2006.

# FACULTY

## Planning Committee

Tin Aung (co-chair), Singapore  
Paul Foster (co-chair), UK  
David S. Friedman (co-chair), USA  
Robert N. Weinreb (chair), USA

## Consensus Development Panel

Makoto Araie, Japan  
Tin Aung, Singapore  
Paul Foster, UK  
David S. Friedman, USA  
Ivan Goldberg, Australia  
Daniel Grigera, Argentina  
Jeffrey Liebmann, USA  
Ravi Thomas, India  
Robert N. Weinreb, USA

## Participants

Poul Helge Alsbirk, Norway  
Mario Aquino, Philippines  
Makoto Araie, Japan  
Somkiat Asawaphureekorn, Thailand  
Augusto Azuara Blanco, UK  
Yaniv Barkana, Israel  
Andreas Boehm, Germany  
Alain Bron, France  
Don Budenz, USA  
Roberto Carassa, Italy  
Robert Casson, Australia  
GC Chandrasekhar, India  
Paul Chew, Singapore  
Anne Coleman, USA  
Nathan Congdon, USA  
Jonathan Crowston, Australia  
Ataya Euswas, Thailand  
Seng Kheong Fang, Malaysia  
David Garway Heath, UK  
Gus Gazzard, UK  
Jian Ge, China  
Ronnie George, India  
Christopher Girkin, USA  
Ivan Goldberg, Australia  
David Greenfield, USA  
Franz Grehn, Germany

Erik Greve, NL  
Daniel Grigera, Argentina  
Mingguang He, China  
Paul Healey, Australia  
Roger Hitchings, UK  
Por Hung, Taiwan  
Aiko Iwase, Japan  
Aliza Jap, Singapore  
Jost Jonas, Germany  
Kenji Kashiwagi, Japan  
Peng Khaw, UK  
Theodore Krupin, USA  
Young Kwon, USA  
Jimmy Lai, Hongkong  
Dennis Lam, Hongkong  
Hans Lemij, NL  
Jeffrey Liebmann, USA  
Arthur Lim, Singapore  
Lance Liu, Australia  
Da Lu  
Baskaran Mani, India  
Felipe Medeiros, USA  
Winnifred Nolan, UK  
Francis Oen, Singapore  
Maria Papadopoulos, UK  
Ki Ho Park, Korea  
Harry Quigley, USA  
Ropilah Rahman, Philippines  
Serge Resnikoff, USA  
Robert Ritch, USA  
Prin RojanaPongpun, Thailand  
Lisandro Sakata, USA  
John Salmon, UK  
Steve Seah, Singapore  
Jovina See, Singapore  
Peter Shah, UK  
Ramanjit Sihota, India  
Kuldev Singh, USA  
Gregory Skuta, USA  
Scott Smith, USA  
Boon Song  
George Spaeth, USA  
Remo Susanna, Brazil  
Visni Tantisevi, India



Chaiwat Teekhasaenee, Thailand  
Clement Tham, Hongkong  
Ravi Thomas, India  
John Thygesen, Denmark  
Goji Tomita, Japan  
Carlo Traverso, Italy  
Lingam Vijaya, India  
Martin Wand, USA

Ningli Wang, China  
Tsing Hong Wang, Taiwan  
Tony Wells, New Zealand  
Tetsua Yamamoto, Japan  
Jennifer Yip, Singapore  
Liang Yuanbo, China  
Jialiang Zhao, China

**Glaucoma Societies / Sections of the following countries and regions have agreed to review this report:**

America, Argentina, Asian-Oceania, Australia and New Zealand, Austria, Belgium, Bulgaria, Canada, Chile, China, Colombia, Croatia, Czech Republic, Denmark, Egypt, Europe, Finland, Germany, Greece, Ghana, Hungary, Iceland, India, Israel, Italy, Japan, Latin-America, Mexico, Netherlands, Norway, Pan American, Pan Arab African, Philippines, Poland, Portugal, Romania, Russia, Serbia and Montenegro, South Africa, South East Asia, Spain, Sweden, Switzerland, Taiwan, Turkey, UK and Eire, Ukrainia, Glaucoma Research Society, Optometric Glaucoma Society, International Society for Glaucoma Surgery.

# CONTENTS

Foreword, Robert N. Weinreb and Erik L. Greve	xi
Preface, David S. Friedman, Paul Foster, Tin Aung and Robert N. Weinreb	xiii
<b>Epidemiology, Classification and Mechanism</b>	
Co-chairs: Paul Foster, Mingguang He, Jeffrey Liebmann	1
<b>Management of Acute Angle Closure Crisis</b>	
Co-chairs: Harry Quigley, Tetsua Yamamoto	21
<b>Surgical Management of Primary Angle Closure Glaucoma</b>	
Co-chairs: Tin Aung, Prin RojanaPongpun, John Salmon	27
<b>Laser and medical treatment of Primary Angle Closure Glaucoma</b>	
Co-chairs: Robert Ritch, Winnie Nolan, Dennis Lam	37
<b>Detection of Primary Angle Closure and Angle Closure Glaucoma</b>	
Co-chairs: David S. Friedman, Ravi Thomas, Poule Helge Alsbirk, Gus Gazzard	55
<b>Appendix A: Development of the Anterior Chamber</b>	
Lance Liu (MBBS, FRANZCO)	65
<b>Appendix B: Ultrasound Biomicroscopy</b>	
Jeffrey Liebmann	71
<b>Appendix C: Devices for Screening for Angle Closure</b>	
M. Baskaran	73
<b>Appendix D: Cost Effectiveness (CEA) of Screening for Primary Angle-Closure Glaucoma</b>	
Augusto Azuara Blanco and Jennifer Yip	75
<b>Glossary</b>	97
<b>Index of Authors</b>	98



Erik L. Greve



Robert N. Weinreb

# FOREWORD

This is the third Consensus Book published under the auspices of AIGS. As with prior consensus reports, this one has great potential to impact patients, both individually and collectively. Reports for this consensus were prepared and discussed using the same internet based e-Room system as used with the previous two reports. The Consensus Faculty consisted of the leading authorities in Angle Closure, with representatives from six continents. These 110 experts dedicated their knowledge, time, and insight to the preparation of the reports between January 1 and May 1, 2006. Prior to the meeting, each of the AIGS member Glaucoma Societies was sent a draft of the consensus report for comment. Each member Society also was invited to send a representative to attend the consensus meeting. The report then was discussed extensively during the Consensus Meeting that was held in Hollywood, Florida on May 3, 2006. Reports and Consensus Statements were revised following these discussions.

Consensus is based on the published literature and expert experience. While one strives to practice evidence-based medicine, many aspects in ophthalmologic practice have not been subject, or are not amenable, to long-term prospective randomized controlled trials. Though expert consensus is not a surrogate for rigorous scientific investigation, it does have value, in particular, where the appropriate evidence is lacking. Generating consensus in expert opinion for Angle Closure therefore aims to derive the most appropriate management for our patients and will highlight areas where further research is required.

Robert N. Weinreb, Consensus Chair, AIGS  
Erik L. Greve, Executive Vice President, AIGS

*“But if you can assemble a diverse group of people who possess varying degrees of knowledge and insight, you’re better off entrusting it with major decisions rather than leaving them in the hands of one or two people, no matter how smart those people are.”*

James Surowiecki, *The Wisdom of Crowds*, 2004



Robert N. Weinreb, Consensus Chair, opening the consensus meeting.



Ivan Goldberg, AIGS President, welcoming the distinguished members of the consensus panel and guests.

# PREFACE

This is the third glaucoma consensus held under the auspices of the AIGS. It is anticipated that the discussions and conclusions from this consensus will impact care of patients with Angle Closure and Angle Closure Glaucoma significantly. As with the previous consensus meetings on Glaucoma Diagnosis and Open Angle Glaucoma Surgery, the consensus reports were developed over several months in an interactive internet system. The Consensus faculty, consisting of leading authorities on Angle Closure from throughout the world, met in Fort Lauderdale on May 3, 2006 to discuss the reports and refine the consensus points.

Primary Angle-Closure Glaucoma is a leading cause of blindness throughout Asia, and may be more common in European-derived populations than previously recognized. Even though Open-Angle Glaucoma is more common than primary Angle Closure Glaucoma, it has been estimated that nearly half of all glaucoma blindness is due to Angle Closure Glaucoma because it tends to be more severe. Further, an aging population should increase the number of individuals affected by Angle Closure Glaucoma. Clearly, strategies need to be articulated to face this challenge.

There has been an explosion of research on Angle Closure and Angle Closure Glaucoma during the past two decades. Ultrasound biomicroscopy provided information about the angle that had been hidden from an observer using only a conventional slit lamp. This had led to changes in our understanding about the mechanisms of disease as well as our approaches to disease management. Even the basic terminology used to discuss Angle Closure and Angle Closure Glaucoma has changed. Newer instruments, such as anterior segment OCT, now offer the promise of even more detailed assessment of the anterior chamber angle. Nevertheless, our current management of patients with Angle Closure Glaucoma remains similar to what it was decades ago, starting with iridotomy and performing additional surgeries as needed.

Trying to determine best practices for Angle Closure and Angle Closure Glaucoma with the rapidly growing literature on the topic is daunting. As with the previous two AIGS consensus, the Angle Closure Consensus is based on the published literature and expert experience. Although consensus does not replace and is not a surrogate for scientific investigation, it does provide considerable value, in particular, when the desired evidence is lacking. The goal of this consensus was to establish what we 'know' and what we need to 'know' to better elucidate the mechanisms, and optimal screening and treatment strategies for angle closure. It is expected that this consensus report will serve as a benchmark for our current understanding, and that it will be revised and improved with the emergence of new evidence.

David S. Friedman  
Paul Foster  
Tin Aung  
Robert N. Weinreb



David S. Friedman – Angle Closure Consensus, co-chair.



Paul Foster – Angle Closure Consensus, co-chair.



Tin Aung – Angle Closure Consensus, co-chair.

# EPIDEMIOLOGY, CLASSIFICATION AND MECHANISM

*Co-chairs:* Paul Foster, Mingguang He and Jeffrey Liebmann



Paul Foster

*Issues in the Epidemiology and Population-Based Screening of Primary Angle Closure Glaucoma* provides an excellent review of the issues that surround the epidemiology and classification of angle closure glaucoma.<sup>1</sup> It is estimated that the number of people affected by glaucoma worldwide will be approximately 60.5 million in 2010, with 44.7 million people affected by POAG and 15.7 million by PACG. The total with PACG will increase to 21 million, with 5.3 million bilaterally blind from this condition in 2020.<sup>2</sup> The World Health Organization ranks glaucoma as the second most common cause of blindness after cataract.<sup>3</sup> The data contained in these publications, and those in subsequent work, point toward the following principles. First, angle closure glaucoma (ACG) causes nearly half of all glaucoma blindness worldwide. Second, ACG is more common among Asians than Caucasians or Africans. Finally, the natural history of ACG is of an asymptomatic disease in the majority of sufferers (66 to 75% of cases). Data from Asia have increased considerably over the last decade. However, while there are several robust studies from India,<sup>4-7</sup> and for East Asian people outside China,<sup>8-11</sup> there are currently very limited data from the People's Republic of China, and from the Southeast Asian countries.<sup>12,13</sup>

## Risk factors

Major demographic risk factors for angle closure are older age, female gender and Asian ancestry.<sup>6,8,9,11,12,16-17</sup> Smaller anterior segment dimensions are the major ocular risk factor, with limbal and axial anterior chamber depth the most strongly correlated with angle closure and angle closure glaucoma.<sup>18,19</sup> The association between older age, female gender and angle closure are explicable on the basis of differences in anterior segment biometry. Women have shallower anterior chambers (AC) than men, and older people have shallower AC than younger people.<sup>20,21</sup> The reason for higher rates of angle closure in Asians remains controversial.<sup>22,23</sup> However, as a general principle, the populations with

*Angle Closure and Angle Closure Glaucoma*, pp. 1-20

edited by Robert N. Weinreb

© 2006 Kugler Publications, The Hague, The Netherlands



the highest rates of angle closure have the shallowest anterior chambers. Family history has been suggested as a risk factor, but is not universally recognized. No genetic associations have yet been conclusively proven.

Ocular risk factors include:

- Narrower drainage angles;
- Shallower axial and limbal anterior chamber depth;
- Thicker lens;
- Shorter axial length;
- More anteriorly positioned lens;
- Smaller corneal diameter;
- Hypermetropic refraction.

## Classification

Classification systems provide a framework for describing the presence and severity of disease, why it occurs, and how different treatments will benefit patients. In most fields of medicine, as understanding of the disease increases, these systems have typically evolved from descriptions of a combination of symptoms, through an understanding of anatomical location of abnormalities, to the etiology and pathogenesis. For clinical purposes, it is highly desirable if a classification scheme both helps to describe how and why a patient suffers from a specific disease process, as well as how to manage the condition most effectively. Indeed an appropriate system of classification is crucial for achieving the highest standards of clinical care. Ultimately, every patient is unique, and should be treated as such. However, it is only possible to make progress in understanding disease processes, and how best to control them, by looking for common patterns through formal study, *i.e.*, through research. Outcomes from clinical trials cannot be compared unless the broad concepts of disease classification are uniform. The study of prevalence and incidence of disease will only yield meaningful results if classifications used reflect characteristics of importance. Some may feel there is 'dichotomy of purpose' between clinic and research. Indeed, in a clinical setting, a myriad of clinical signs may be identified, and have relevance to the care of the patient. Identification and assimilation of these signs into a management plan is a complex process requiring many years of training and experience to master. Codifying such complex decision making processes is beyond the scope of this section of the review. However, as modern medical science adopts a progressively more evidence-based approach, the principles of management increasingly are based on systematic research. Major advantages of a standard classification scheme are the promotion of a common language used by all involved, clarification of thought processes around disease mechanisms and disease (or pre-disease state) prognosis, and the ability to make valid comparisons between datasets.

## The evolution of classification schemes for angle closure glaucoma

Acute angle closure glaucoma was probably the first form of glaucoma to be recognized as a separate diagnostic entity from cataract. Von Graefe described the surgical peripheral iridectomy as a method of treating glaucoma. Initial classifications of glaucoma evolved to identify congestive, post-congestive and absolute stages of disease, identifying both a symptomatic course with an acute episode causing pain and inflammation, as well as an asymptomatic form (either of which could lead to total blindness). The advent of gonioscopy was a significant step forward in sophistication of diagnostic methodology and potential for understanding the pathological mechanisms responsible for angle closure. It allowed the relationship between iris and trabecular meshwork to be observed directly in patients for the first time. More recently, the advent of anterior segment imaging has allowed a clearer understating of gonioscopic observations and the mechanisms that cause narrowing of the anterior chamber angle.<sup>24,25</sup>

Researchers in the past have classified angle closure into three sub-categories, based on presence or absence of symptoms.

- *Acute*: abrupt onset of symptomatic elevation of IOP resulting from total closure of the angle which is typically not self limiting (although acute attacks can rarely resolve spontaneously);
- *Sub-acute or intermittent*: abrupt onset of symptomatic elevation of IOP resulting from closure of the angle which is self limiting and recurrent;
- *Chronic*: elevated IOP or PAS resulting from angle closure that is asymptomatic.

Some researchers have also described a fourth subcategory, '*latent*' angle closure, which is evidence that angle closure is either likely or may have occurred intermittently. Evidence includes a positive provocative test or the finding of primary peripheral anterior synechiae (PAS) in an eye that has an open but narrow angle. However, this term is no longer used, perhaps because PAS with or without elevated IOP is considered chronic angle closure.

An advantage of defining glaucoma as acute, sub-acute, or chronic is that it is familiar to doctors and easy to understand for patients who have a symptomatic episode of angle closure. However, the implicit assumption within this system is that most angle closure is symptomatic. The scheme has evolved ad-hoc from early clinical observations, and reflects a level of understanding of natural history and pathology that is less complete than the one we have today. It has no evidence base and no proven validity in predicting prognosis. The major flaws are an absence of emphasis on the presence or risk of significant loss of visual function, and the fact that it does nothing to guide the ophthalmologist in devising a logical management plan. Moreover, the term 'glaucoma' is attached to all grades of disease, regardless of presence or absence of optic neuropathy.

### Definition of an ‘occludable’ angle

The threshold at which angle closure is considered as a possible diagnosis is not clearly defined. The concept of defining the threshold by describing the characteristics of an ‘occludable’ angle is both logical and pragmatic. The terms ‘narrow’ and ‘occludable’ are generally seen as synonymous, and are used to indicate the anatomical predisposition to angle closure. However, debate surrounds the use of each. The epidemiological research standard used for defining ‘occludable’ angles in studies in Alaska, South Africa, Mongolia, Singapore, Bangladesh and China was: The posterior (usually pigmented) trabecular meshwork is obstructed by the peripheral iris for three quarters or more of its circumference.

This was first described by Arkell *et al.* for their study in Alaska,<sup>15</sup> and used by John Salmon and Paul Foster to allow comparison among studies.<sup>9,10,16</sup> However, around half of all participants in population studies who do have ‘primary’ PAS (no other identifiable cause) are excluded by this definition.<sup>26</sup> Thomas used 180 degrees of iridotrabecular contact (ITC) in his cross-sectional and longitudinal studies in Vellore, southern India.<sup>27,28</sup> This slightly more liberal threshold is still likely to exclude many people who have primary PAS or appositional angle closure.<sup>26</sup> Becker and Shaffer originally suggested that an iridotrabecular angle of 20 degrees was the threshold at which angle closure should be considered a possibility.<sup>29</sup> This probably represents the most inclusive of approaches.

Nonetheless, an evidence-based assessment of our current definition of ‘risk’ (*i.e.*, an occludable angle) shows that the current diagnostic threshold (*i.e.*, 180–270 degrees of ITC) is far too stringent. Gonioscopy using visible light probably under-detects cases where ITC is occurring. A strong case can be made in favor of shifting the burden of proof from the current stance that requires we prove a patient HAS angle closure to proving that a patient DOES NOT have angle closure. As angle closure can potentially be ‘cured’ with early detection and a single laser procedure, it may be that ophthalmologists are missing an opportunity to provide effective therapy to many individuals with gonioscopically narrow angles that result in appositional closure throughout the day. Expanding the definition of a narrow or ‘occludable’ angle will allow for better consideration of this possibility through research and clinical practice.

### Classification of angle closure in epidemiological research

A classification for use in prevalence surveys and other epidemiological research has been published by Foster and colleagues.<sup>30</sup> It identifies three conceptual stages in the natural history of angle-closure from ITC, to anterior segment signs of disease (raised IOP and/or PAS), and culmination in glaucomatous optic neuropathy.

1. *Primary angle closure suspect (PACS)*: ITC in three or more quadrants, but normal IOP, disc and field, without evidence of PAS;
2. *Primary angle closure (PAC)*: ITC in three or more quadrants with either raised IOP and/or primary PAS. Disc and field are normal;
3. *Primary angle closure glaucoma (PACG)*: ITC in three or more quadrants plus evidence of glaucomatous damage to optic disc and visual field (with similar approaches as those used for POAG).

Glaucomatous optic neuropathy has been defined in this scheme using three levels of evidence. Category 1 stipulates structural and functional abnormalities consistent with glaucoma. Category 2 stipulates that in the case of advanced loss of vision where field testing cannot be performed using automated perimetry, glaucoma can be diagnosed on the basis of advanced structural damage to the optic disc. Category 3 applies to cases where the disc cannot be seen. Glaucoma is diagnosed on the basis of visual acuity  $< 3/60$  and either IOP  $> 24$  mmHg or signs of previous filtering surgery. Admittedly, this criterion is somewhat arbitrary and could at times result in misclassifications. It has been proposed that this category be expanded to include those with iris ischemic sequelae (iris whorling, poorly reactive pupils, and iridoschisis) and either an afferent pupil defect or no light perception. It is recognized this scheme makes no allowance for variation in disc size, and that this is an important (previously recognized) omission.<sup>30,31</sup>

This scheme has been employed in research and the incidence of each category has been estimated.<sup>27,28</sup> Accurate classification in any study requires appropriate indentation gonioscopy. In addition, it is useful to record physical signs in the anterior segment of ischemia (distortion of radial iris fibers), or necrosis (sub-capsular opacities in the lens-glaucomfleken). There is no consensus on whether subcategories of PAC that are ischemic and non-ischemic should be included in the classification of subjects.

The major deficiency with the above approach is that it does not identify the mechanism responsible for angle closure, and requires an additional scheme to be used in parallel for this purpose. However, it does indicate the presence or absence of abnormalities requiring treatment, and specifies visually-significant end-organ damage (glaucomatous optic neuropathy). Moreover, there are several other causes of ocular tissue damage and visual dysfunction that are associated with angle closure, and should be separately identified in clinical management and research assessment of individuals with this condition. Description of these factors adds an additional level of clinical sophistication if desired. These include:

- Corneal endothelial loss;
- Trabecular meshwork damage;
- Lens damage (glaucomfleken and cataract);
- Iris damage (iris ischemia, chronic dilation, unresponsive pupil, iridoschisis, ectropion uveae);

- A flat, pale optic disc similar in appearance to that of anterior ischemic optic neuropathy;
- Glaucomatous optic neuropathy.

### **Trabecular meshwork damage in angle closure**

In some persons, PAC causes damage to the eye in addition to glaucomatous optic neuropathy. It seems most likely that all three of these processes (apposition, TM failure and PAS) are co-existent in the same eye.

- *Appositional closure causing a pre-trabecular outflow obstruction*  
This is the primary mechanism in symptomatic 'acute' PAC. This is also the predominant mechanism in asymptomatic presentations, at least in the early stages of disease. The justification for linking this with long-term prognosis comes from incidence data from Vellore, although the small numbers in the treated and untreated sub-groups make it necessary to have corroborating data for this.<sup>30</sup> These results are consistent with widely held consensus views regarding the natural history of the disease and are reflected in current clinical practice patterns.
- *Appositional closure causing a trabecular-level outflow obstruction*  
It is biologically plausible that long-term, low-grade contact and friction between TM and iris causes alteration of TM structure and function. A single histological study reported marked TM degeneration away from areas of PAS in asymptomatic angle closure.<sup>33</sup> This study has such far-reaching and profound implications for the future diagnosis and management of glaucoma, that it must be verified by independent groups, and using other lines of investigation. Epidemiological data support this finding, as higher IOP occurs in open but narrower angles.<sup>34</sup>
- *Synechial closure*  
This is the most plausible, and well recognized, route to deteriorating outflow facility. The extent of synechial closure is associated with the degree of elevation of intraocular pressure.<sup>34-37</sup>

### **An anatomic basis for primary angle closure mechanisms**

The angle closure disorders are characterized by the presence of iridotrabecular contact (ITC), which may lead to trabecular dysfunction, peripheral anterior synechiae (PAS), elevated intraocular pressure (IOP), glaucomatous optic neuropathy, glaucomatous functional loss, and blindness.

Angle closure can be caused by one or a combination of abnormalities in the relative or absolute sizes or positions of anterior segment structures or abnormal forces in the posterior segment that may alter the anatomy of the anterior

segment. Angle closure may be understood by regarding it as resulting from blockage of the trabecular meshwork caused by forces acting at four successive anatomic levels: the iris (most commonly, pupillary block), the ciliary body (most commonly, plateau iris), the lens (phacomorphic glaucoma), and vectors posterior to the lens (malignant glaucoma). This classification, devised by Ritch and colleagues,<sup>38</sup> facilitates understanding of the various mechanisms and appropriate treatment. Each level of block may have a component of each of the levels preceding it and in some patients multiple mechanisms play a role. The appropriate treatment becomes more complex for each level of block, as each level may also require treatments for lower levels of block.

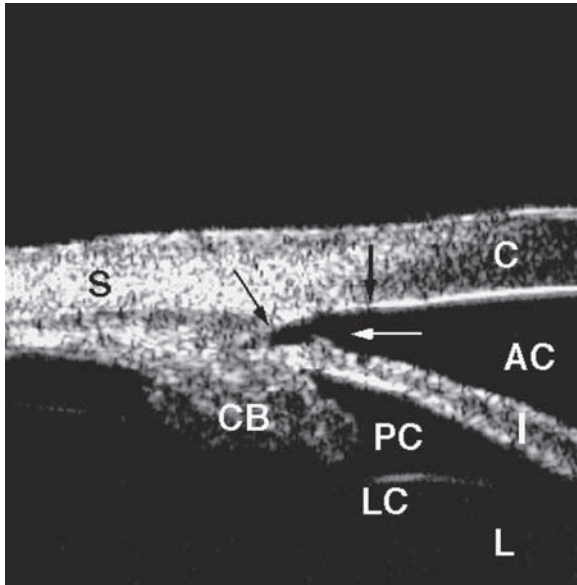
### **Classification system of the angle closure glaucomas<sup>1,2</sup>**

*Level I, Iris and Pupil:* Pupillary block is the most common form of angle closure glaucoma. In pupillary block, flow of aqueous from its site of production by the non-pigmented ciliary epithelium in the posterior chamber to the anterior chamber is limited because of resistance to aqueous flow through the pupil in the region of iridolenticular contact. This limitation creates a relative pressure gradient between the anterior and posterior chambers, and forces the iris anteriorly, causing anterior iris bowing, narrowing of the angle, and acute or chronic ITC or ACG. The anterior segment structures and their anatomic relationships appear otherwise normal, although upon occasion abnormalities of iris architecture (thickness, orientation, muscle tone) may be contributing factors. Pupil block is the most common mechanism of angle closure,<sup>36,41</sup> and the majority with other causes of angle closure have at least an element of pupil-block. In East Asia, mixed mechanism angle closure is believed to be especially prevalent.<sup>42</sup>

Using high frequency, high resolution, ultrasound biomicroscopy (UBM), the structures surrounding the posterior chamber, previously hidden from clinical observation, can be imaged and their anatomic relationships assessed. This technology has enhanced the development of an anatomic classification of the angle closure glaucomas (Figs. 1 and 2). Anterior segment imaging using optical coherence tomography (OCT) offers the potential for viewing the anterior chamber angle without contact.

Laser iridotomy eliminates the pressure differential between the anterior and posterior chambers and relieves the iris convexity. This results in several changes in anterior segment anatomy. The iris assumes a flat or planar configuration and the iridocorneal angle widens. The region of iridolenticular contact increases, as aqueous flows through the iridotomy rather than the pupillary space (Fig. 3).

*Level II, Ciliary body architecture:* Abnormal ciliary body position or development leads to angle closure because of anteriorly positioned ciliary processes, which force the peripheral iris into the angle (Fig. 4) and is termed plateau iris.

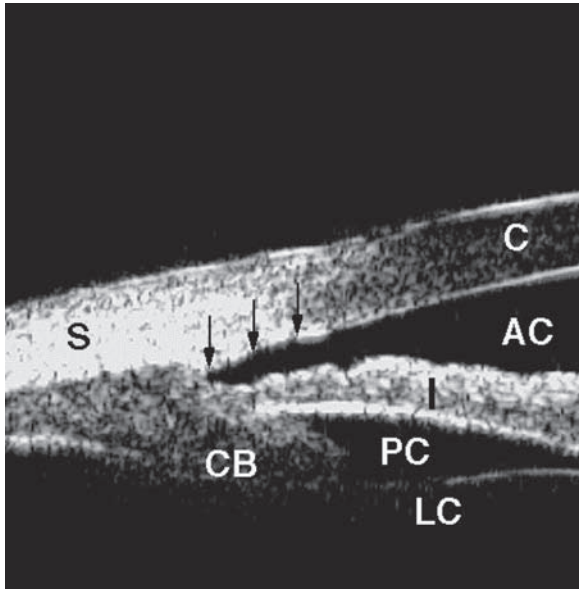


*Fig. 1.* The ultrasound biomicroscopic appearance of normal eye. The cornea (C), anterior chamber (AC), iris (I), lens (L), lens capsule (LC), posterior chamber (PC), angle (arrow), scleral spur (thin arrow), Schwalbe's line (thick arrow) sclera (S), and ciliary body (CB) are visible.

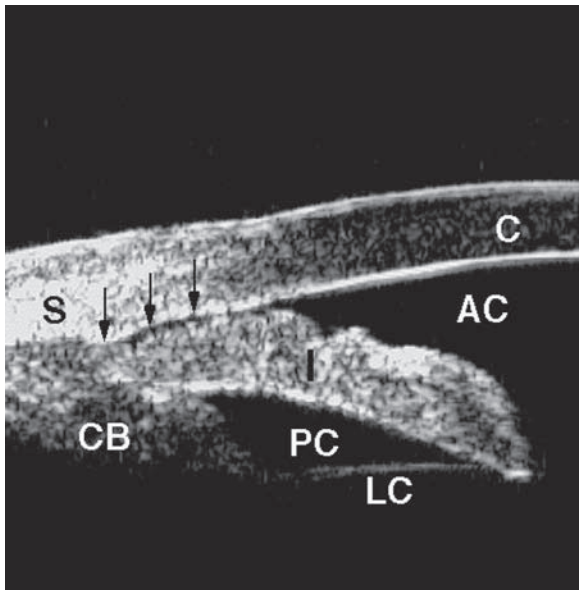
On gonioscopy, the iris root angulates forward and then centrally. The iris root may be short and inserted anteriorly on the ciliary face, producing a shallow, narrow angle with a sharp drop-off of the peripheral iris. Before iridotomy, the anterior chamber is usually of medium depth and the iris surface mildly convex. Laser iridotomy either fails to open the angle or opens it only partially. Argon laser peripheral iridoplasty may open the angle in this circumstance. Regarding plateau iris, there is no precise quantitative definition of how narrow the angle has to be or how anteriorly positioned the ciliary processes must be before the diagnosis of plateau iris is made.<sup>43,44</sup> There are many causes of an apparent plateau iris configuration.<sup>45</sup> The absence of ciliary sulcus was observed in 41% (9/22) eyes with open angle (angle-opening distance measured using UBM at 500 microns from the scleral spur (AOD500) > 130 microns) after iridotomy, suggesting that this finding is not necessarily related to an anterior positioning of the ciliary process.<sup>46</sup>

Plateau iris syndrome refers to the development of angle closure, either spontaneously or after pupillary dilation, in an eye with plateau iris configuration despite the presence of a patent iridotomy. Some patients may develop acute angle closure. The extent, or the 'height' to which the plateau rises, determines whether the angle will close completely or only partially. The angle can narrow further with age due to enlargement of the lens, so that an angle with plateau configuration which does not close after iridotomy may do so some



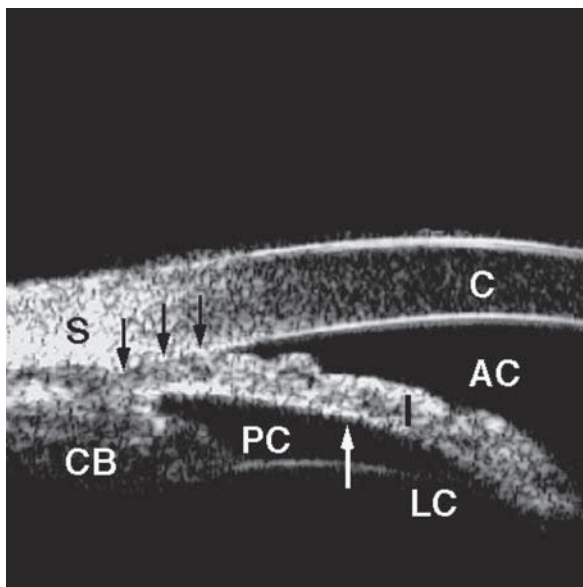


*Fig. 2. A.* The effect of illumination on angle configuration (bright illumination). Under normal conditions, the miotic response to light causes the angle to open. Aqueous has access to the trabecular meshwork (arrows).

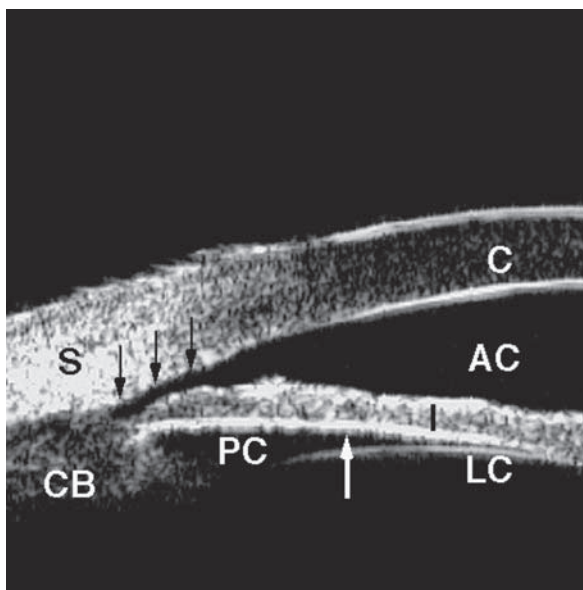


*Fig. 2. B.* The effect of illumination on angle configuration. If the room illumination is dimmed during scanning of the patient shown in A, pupillary dilation may cause the peripheral iris to crowd the angle and become apposed to the trabecular meshwork, causing angle closure.

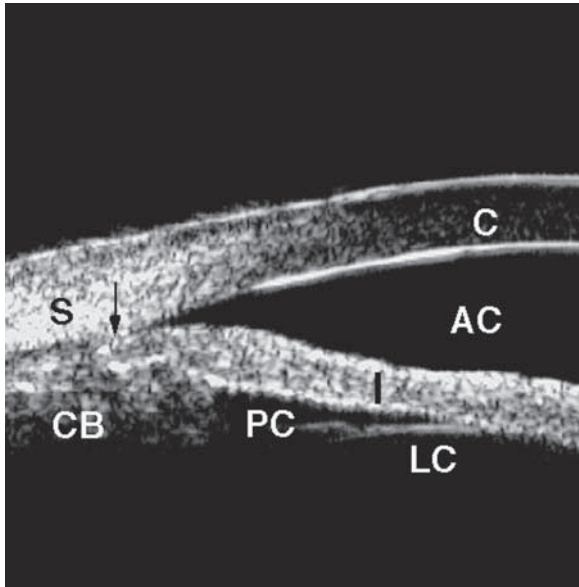




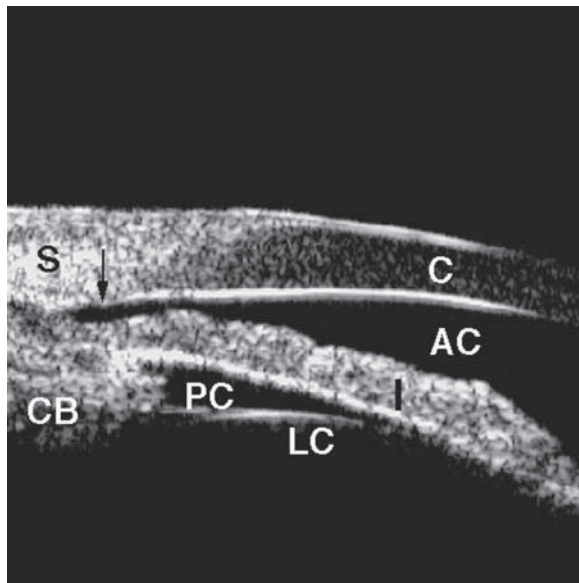
*Fig. 3. A.* In pupillary block angle closure, the iris has a convex configuration (white arrow), because of the relative pressure differential between the posterior chamber (the site of aqueous production) and the anterior chamber. The angle is closed (black arrows).



*Fig. 3. B.* Following laser iridotomy, aqueous has free access to the anterior chamber and the pressure gradient is eliminated. The iris assumes a flat (planar) configuration and the angle opens.



*Fig. 4. A.* In plateau iris syndrome, the physical presence of the ciliary body forces the peripheral iris into the angle and closes the angle. Iridotomy relieves the contribution of pupillary block component to the angle narrowing, but not the closure related to the abnormal ciliary body position. The scleral spur is visible (arrow).



*Fig. 4. B.* Laser iridoplasty may be used in plateau iris syndrome to relieve appositional angle closure.

years later. Periodic gonioscopy is recommended. Other disorders of the ciliary body that may rarely mimic plateau iris configuration include iridociliary cysts, tumors or edema.

*Level III, Lens-induced glaucoma:* Anterior lens subluxation or intumescence may precipitate acute or chronic angle closure glaucoma (phacomorphic glaucoma) due to the lens pressing against the iris and ciliary body and forcing them anteriorly.

*Level IV, Malignant glaucoma* (Fig. 5). Also known as ciliary block, angle closure caused by forces posterior to the lens which push the lens-iris diaphragm forward presents the greatest diagnostic and treatment challenge of the angle closure glaucomas. Analogous to pupillary block, in which the angle is occluded by iris because of a pressure differential between the posterior and anterior chambers, in ciliary block, a pressure differential is created between the vitreous and aqueous compartments by aqueous misdirection into the vitreous.

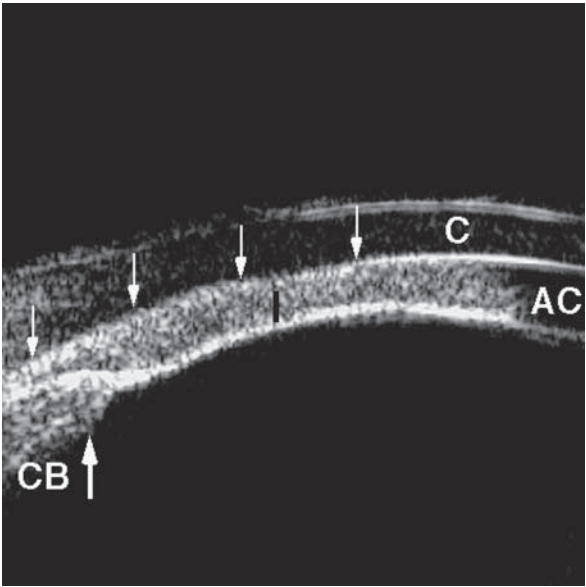
Swelling or anterior rotation of the ciliary body with forward rotation of the lens-iris diaphragm and relaxation of the zonular apparatus causes anterior lens displacement which in turn causes direct angle closure by physically pushing the iris against the trabecular meshwork. A shallow supraciliary detachment not evident on routine B-scan examination may be present. This effusion appears to be the cause of the anterior rotation of the ciliary body and the forward movement of the lens-iris diaphragm.

*Other causes of angle closure:* The angle may be closed by other disease processes, including anterior subluxation of the lens, iris or ciliary body cysts, enlargement of the ciliary body due to inflammation or tumor infiltration, and air or gas bubbles after intraocular surgical procedures. Anterior chamber process that may also cause peripheral anterior synechiae include iris and angle neovascularization, iridocorneal endothelial syndrome, or anterior uveitis. These disorders should be identified and treated specifically. A summary of the mechanisms is provided in Table 1.

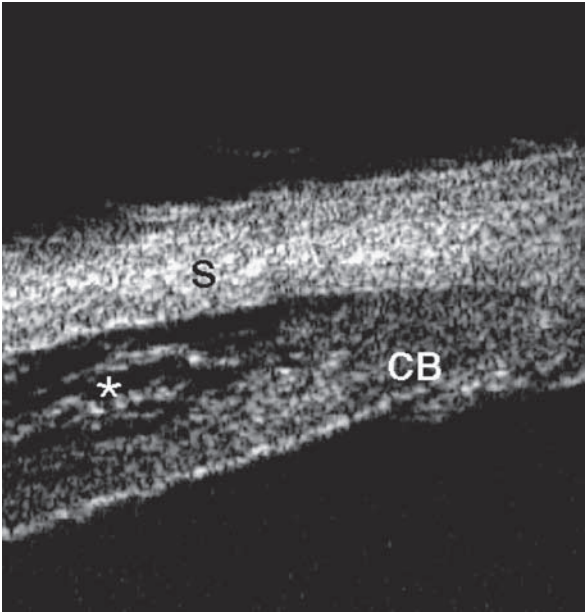
## Gonioscopy

**Gonioscopy is a required feature of the initial eye examination. Without gonioscopy, glaucoma cannot be evaluated or treated properly.**

Gonioscopy remains the ‘reference standard’ for diagnosing angle closure, although imaging techniques such as UBM and anterior segment OCT may prove to be more reliable predictors of outcome than gonioscopy. Gonioscopy requires contact with the globe and, in addition to the potential for discomfort, is also likely to result in some distortion of cornea and angle in some cases.



*Fig. 5. A.* Malignant glaucoma can result from aqueous misdirection or from annular ciliary body detachment.



*Fig. 5. B.* In the latter case, fluid is visible in the supraciliary space (asterisk). In either case, anterior rotation of the ciliary body (white arrow) about its insertion into the scleral spur may cause a secondary angle closure glaucoma (black arrow).

Table 1. Mechanisms of angle closure glaucoma

- 
- I. Pupillary block
    - A. Relative pupillary block (primary angle closure)
    - B. Miotic induced angle closure
    - C. Posterior synechiae
      - 1. Crystalline lens
      - 2. Intraocular lens
      - 3. Anterior hyaloid face
  - II. Plateau iris
    - A. True plateau iris
    - B. Pseudoplateau iris – Iris and ciliary body cysts
  - III. Lens-induced angle closure
    - A. Intumescent lens (phakomorphic)
    - B. Anterior lens subluxation
      - 1. Trauma
      - 2. Exfoliation syndrome
      - 3. Hereditary disorders
    - C. Drug sensitivity, *e.g.*, sulfonamides
  - IV. Malignant (ciliary block) glaucoma
    - A. Primary
      - 1. Phakic
      - 2. Pseudophakic
      - 3. Aphakic
    - B. Secondary
      - 1. After panretinal photocoagulation
      - 2. After scleral buckling procedures
      - 3. After central retinal vein occlusion
      - 4. Intraocular tumors
      - 5. Posterior scleritis
      - 6. Retrolenticular tissue contracture
        - a. Retinopathy of prematurity
        - b. PHPV
      - 7. Uveal effusion from adjacent inflammation
        - a. Posterior scleritis
        - b. AIDS
- 

There are three widely used clinical grading schemes – each scheme has its own strengths and weaknesses. The Scheie scheme (structures seen) is simple and intuitive for non-specialists.<sup>47</sup> The number of structures seen varies considerably, depending on direction of gaze and orientation of the gonioscope. The Shaffer scheme is more logical for assessing risk in narrow but open angles, in that it requires an assessment of geometric angular distance between iris and cornea.<sup>29</sup> The accuracy of the assessment of angle width is dependent on experience. The Spaeth scheme allows the most detailed recording of angle characteristics (geometric angle, iris profile, true and apparent level of insertion).<sup>48</sup> Although useful in research and for some clinicians, it may be too cumbersome for many general ophthalmologists. With each of these schemes, it is desirable

to describe what is observed to complement derivative numbering schemes (0-4, or 0-IV).

The best lens to use remains controversial. The ability to use a 4-mirror lens in which the lens diameter is less than the corneal diameter is mandatory. Alternatively, some closed angles can be indented open using a Goldmann lens. This lens offers the opportunity of a more stable, clear view, and will probably give the occasional or inexperienced user more confidence in identifying important landmarks. However, since many appositionally closed angles cannot be indented open using this lens, the use of a 4-mirror lens is necessary.

Gonioscopy in a darkened room is preferred for determining the angle configuration. This test should be performed in a room with the lights extinguished and the door closed and the smallest square of slit-lamp illumination that will enable a view of the angle. The degree of angle narrowing is often much greater than expected. Angle narrowing can often be demonstrated by changing the slit lamp illumination during gonioscopy (Fig. 6). When examining an eye with an anatomically narrow angle, angle closure or suspected occludability, the corneal wedge helps to identify landmarks. Additionally, it is important to note the location of the scleral spur, which is a clinically important landmark. The trabecular meshwork is located directly anterior to this structure. The anatomy of the normal eye is demonstrated in Figure 7.

Failure to diagnose angle closure is often an important factor in eyes with labile or poorly controlled IOP.

### **Key factors for good gonioscopy**

- Ensure adequate topical anesthesia;
- The room must be dark;
- Start by using a 1 mm, narrow beam of light kept well away from the pupil with the lowest slit lamp illumination that will permit visualization of angle structures;
- Have patient maintain gaze in the primary position;
- Minimize tilting of the lens to that required to see over the convexity of the iris. Only minor movement of the lens is permissible, otherwise the angle findings will be distorted and a closed angle may appear open. While the lens can be shifted along the cornea, care must be taken not to apply pressure with consequent indentation;
- Use high magnification to identify the termination of the corneal wedge, marking the anterior edge of TM;
- Assess whether the iris is in contact with the TM, and if not, estimate the geometric angle between TM and adjacent peripheral area of the iris. Describe the level of the most anterior point of contact between iris and angle structures;
- Once this has been completed for the entire circumference, increase the level

- of illumination and perform a dynamic (indentation/manipulation examination);
- For Goldmann-style lenses, instruct the patient to look toward the mirror, and press on the rim of the lens overlying the mirror (this indents the central cornea);
  - Describe the ‘true’ level of insertion of the iris, as well as the height and circumference of any PAS.

Ultimately, four questions need to be answered, and the answers described as clearly as possible.

- Does the iris touch the TM?
- If not, is there evidence that it has been in contact previously?
- If so, is the contact reversible?
- If not, what is the extent of synechial closure (height and circumference)?

## Consensus statements

### *Classification*

- The proposed classification scheme can be used not only to classify the natural history of angle closure, but also to determine prognosis and describe an individual’s need for treatment at different stages of natural history of the disease.
- Additional clinical sophistication can be gained describing sequelae of angle closure affecting the cornea, trabecular meshwork, iris, lens optic disc and retina. Specifically, the extent of PAS, level of presenting IOP (in asymptomatic cases) and presence of glaucomatous optic neuropathy should be noted.
- Ascertaining the mechanism of angle closure (pupillary block, plateau, lens-related, retro-lenticular) is essential for management, and it should be used in conjunction with a classification of the stage of the disease.

*Comment:* Further refinement of these systems (such as the inclusion of symptoms as a defining feature of angle closure) should be made on the basis of peer-reviewed evidence.

*Comment:* Angle closure can be caused by one or a combination of abnormalities in the relative or absolute sizes or positions of anterior segment structures or abnormal forces in the posterior segment that may alter the anatomy of the anterior segment. Angle closure may be understood by regarding it as resulting from blockage of the trabecular meshwork caused by forces acting at four successive anatomic levels: the iris (pupillary block), the ciliary body (plateau iris), the lens (phacomorphic glaucoma), and vectors posterior to the lens (malignant glaucoma).

- Although the amount of pupillary block may vary among eyes with angle closure, all eyes with angle closure require treatment with iridotomy.

### *Gonioscopy*

- Gonioscopy is indispensable to the diagnosis and management of all forms of glaucoma and is an integral part of the eye examination.
- An essential component of gonioscopy is the determination that iridotrabecular contact is either present or absent. If present, the contact should be judged to be appositional or synechial (permanent).

*Comment:* The terms ‘iridotrabecular contact (stating the number of degrees)’ and ‘primary angle closure suspect’ should be substituted for ‘occludable’, as this is more accurate.

*Comment:* The determination of synechial contact may require indentation of the cornea during gonioscopy, in which case a goniolens with a diameter smaller than the corneal diameter is preferred.

- Access to a magnifying, Goldmann-style lens enhances the ability to identify important anatomical landmarks, and signs of pathology. Although the accuracy of indentation with this lens has not been validated, its use does complement that of a goniolens with a diameter smaller than the corneal diameter. The ideal standard is access to both types of lens.
- Anterior segment imaging devices may augment the evaluation of the anterior chamber angle, but their place in clinical practice still needs to be determined.
- It is desirable to record gonioscopic findings in clear text. Describing the anatomical structures seen, the angle width, the iris contour and the amount of pigmentation in the angle are all desirable.

### **Issues requiring further attention**

- Develop a specific definition of PAS;
- Reconsider including in the definition of PAC(S) those with any ITC or perhaps 180 degrees of ITC, as the current definition (which requires 270 degrees of ITC) excludes around 50% of cases with primary angle closure causing PAS;
- Include disc size when seeking structural changes consistent with glaucoma in the diagnostic algorithm for future epidemiological studies.

### **References**

1. Congdon N, Wang F, Tielsch JM. Issues in the Epidemiology and Population-Based Screening of Primary Angle-Closure Glaucoma. *Surv Ophthalmol* 1992;36:411-423.



2. Quigley HA, Broman AT. The number of persons with glaucoma worldwide in 2010 and 2020. *Br J Ophthalmol* 2006; in press.
3. Resnikoff S, Pascolini D, Etya'ale D, Kocur I, Pararajasegaram P, Pokharel GP, et al. Global data on visual impairment in the year 2002. *WHO Bull* 2004;82:844-851.
4. Dandona L, Dandona R, Mandal P, Srinivas M, John RK, McCarty CA, et al. Angle-closure glaucoma in an urban population in southern india. The Andhra Pradesh eye disease study. *Ophthalmology* 2000;107:1710-1716.
5. Jacob A, Thomas R, Koshi SP, Braganza A, Muliyl J. Prevalence of primary glaucoma in an urban south Indian population. *Ind J Ophthalmol* 1998;46:81-86.
6. Ramakrishnan R, Nirmalan PK, Krishnadas R, Thulasiraj RD, Tielsch JM, Katz J, et al. Glaucoma in a rural population of southern India: the Aravind comprehensive eye survey. *Ophthalmology* 2003;110:1484-1490.
7. Vijaya L, George R, Arvind H, Baskaran M, Paul PG, Ramesh SV, et al. Prevalence of angle-closure disease in a rural southern Indian population. *Arch Ophthalmol* 2006;124:403-409.
8. Shiose Y, Kitazawa Y, Tsukuhara S, Akamatsu T, Mizokami K, Futa R, et al. Epidemiology of glaucoma in Japan – A nationwide glaucoma survey. *Jpn J Ophthalmol* 1991;35:133-155.
9. Foster PJ, Baasanhu J, Alsbirk PH, Munkhbayar D, Uranchimeg D, Johnson GJ. Glaucoma in Mongolia – A population-based survey in Hövsgöl Province, Northern Mongolia. *Arch Ophthalmol* 1996;114:1235-1241.
10. Foster PJ, Oen FT, Machin DS, Ng TP, Devereux JG, Johnson GJ, et al. The prevalence of glaucoma in Chinese residents of Singapore. A cross-sectional population survey in Tanjong Pagar district. *Arch Ophthalmol* 2000;118:1105-1111.
11. Yamamoto T, Iwase A, Araie M, Suzuki Y, Abe H, Shirato S, et al. The Tajimi Study report 2: prevalence of primary angle closure and secondary glaucoma in a Japanese population. *Ophthalmology* 2005;112:1661-1669.
12. Bourne RRA, Sukudom P, Foster PJ, Tantisevi V, Jitapunkul S, Lee PS, et al. Prevalence of glaucoma in Thailand: a population based survey in Rom Klao District, Bangkok. *Br J Ophthalmol* 2003;87:1069-1074.
13. Foster PJ, Johnson GJ. Glaucoma in China: how big is the problem? *Br J Ophthalmol* 2001;85:1277-1282.
14. Alsbirk PH. Primary angle-closure glaucoma. Oculometry, epidemiology, and genetics in a high risk population. *Acta Ophthalmol* 1976;54:5-31.
15. Arkell SM, Lightman DA, Sommer A, Taylor HR, Korshin OM, Tielsch JM. The prevalence of glaucoma among eskimos of Northwest Alaska. *Arch Ophthalmol* 1987;105:482-485.
16. Salmon JF, Mermoud A, Ivey A, Swanevelder SA, Hoffman M. The prevalence of primary angle-closure glaucoma and open angle glaucoma in Mamre, Western Cape, South Africa. *Arch Ophthalmol* 1993;111:1263-1269.
17. Seah SKL, Foster PJ, Chew PT, Jap A, Oen F, Fam HB, et al. Incidence of Acute Primary Angle-closure Glaucoma in Singapore. An Island-Wide Survey. *Arch Ophthalmol* 1997;115:1436-1440.
18. Foster PJ, Devereux JG, Alsbirk PH, Lee PS, Uranchimeg D, Machin D, et al. Detection of gonioscopically occludable angles and primary angle closure glaucoma by estimation of limbal chamber depth in Asians: modified grading scheme. *Br J Ophthalmol* 2000;84:186-192.
19. Devereux JG, Foster PJ, Baasanhu J, Uranchimeg D, Lee PS, Erdenbeleig T, et al. Anterior chamber depth measurement as a screening tool for primary angle-closure glaucoma in an East Asian population. *Arch Ophthalmol* 2000;118:257-263.
20. Alsbirk PH. Anterior chamber depth in Greenland Eskimos. I. A population study of variation with age and sex. *Acta Ophthalmol* 1974;52:551-564.
21. Foster PJ, Alsbirk PH, Baasanhu J, Munkhbayar D, Uranchimeg D, Johnson GJ. Anterior

- chamber depth in Mongolians. Variation with age, sex and method of measurement. *Am J Ophthalmol* 1997;124:53-60.
22. Congdon NG, Qi Y, Quigley HA, Hung PT, Wang TH, Ho TC, et al. Biometry and Primary Angle-closure Glaucoma among Chinese, White and Black populations. *Ophthalmology* 1997;104:1489-1495.
  23. Aung T, Nolan WP, Machin D, Seah SK, Baasanhu J, Khaw PT, et al. Anterior chamber depth and the risk of primary angle closure in 2 East Asian populations. *Arch Ophthalmol* 2005;123:527-532.
  24. Ritch R, Stegman Z, Liebmann J. Mapstone's hypothesis confirmed. *Br J Ophthalmol* 1995;79:300.
  25. Gazzard G, Foster PJ, Friedman DS, Khaw PT, Seah SK. Light to dark physiological variation in irido-trabecular angle width. *Br J Ophthalmol* 2004; Video Supplement.
  26. Foster PJ, Nolan WP, Aung T, Machin D, Baasanhu J, Khaw PT, et al. Defining 'occludable' angles in population surveys: Drainage angle width, peripheral anterior synechiae and glaucomatous optic neuropathy in East Asian people. *Br J Ophthalmol* 2004;88:486-490.
  27. Thomas R, Parikh R, Muliylil J, Kumar R. Five-year risk of progression of primary angle closure to primary angle closure glaucoma: a population-based study. *Acta Ophthalmol Scand* 2003;81:480-485.
  28. Thomas R, George R, Parikh R, Muliylil J, Jacob A. Five year risk of progression of primary angle closure suspects to primary angle closure: a population based study. *Br J Ophthalmol* 2003;87:450-454.
  29. Becker B, Shaffer RN. Diagnosis and therapy of the glaucomas. St Louis: CV Mosby, 1965: 42-53.
  30. Foster PJ, Buhrmann RR, Quigley HA, Johnson GJ. The definition and classification of glaucoma in prevalence surveys. *Br J Ophthalmol* 2002;86:238-242.
  31. Crowston JG, Hopley CR, Healey PR, Lee A, Mitchell P. The effect of optic disc diameter on vertical cup to disc ratio percentiles in a population based cohort: the Blue Mountains Eye Study. *Br J Ophthalmol* 2004;88:766-770.
  32. Alsbirk PH. Anatomical risk factors in primary angle-closure glaucoma. A ten year follow up survey based on limbal and axial anterior chamber depths in a high risk population. *Int Ophthalmol* 1992;16:265-272.
  33. Sihota R, Lakshmaiah NC, Walia KB, Sharma S, Pailoor J, Agarawal HC. The trabecular meshwork in acute and chronic angle closure glaucoma. *Ind J Ophthalmol* 2001;49:255-259.
  34. Foster PJ, Machin D, Wong TY, Ng TP, Kirwan JF, Johnson GJ, et al. Determinants of intraocular pressure and its association with glaucomatous optic neuropathy in Chinese Singaporeans: the Tanjong Pagar Study. *Invest Ophthalmol Vis Sci* 2003;44:3885-3891.
  35. Salmon JF. Long-term intraocular pressure control after Nd-YAG laser iridotomy in chronic angle-closure glaucoma. *J Glaucoma* 1993;2:291-296.
  36. Nolan WP, Foster PJ, Devereux JG, Uranchimeg D, Johnson GJ, Baasanhu J. YAG laser iridotomy treatment for primary angle-closure in east Asian eyes. *Br J Ophthalmol* 2000;84:1255-1259.
  37. Gazzard G, Foster PJ, Devereux JG, Oen F, Chew P, Khaw PT, et al. Intraocular pressure and visual field loss in primary angle closure and primary open angle glaucomas. *Br J Ophthalmol* 2003;87:720-725.
  38. Ritch R, Lowe RF. In: Ritch R, Shields MB, Krupin T (eds). *The Glaucomas*. 2nd ed. St. Louis: Mosby, 1996: 801.
  39. Ritch R, Liebmann J, Tello C. A construct for understanding angle-closure glaucoma: the role of ultrasound biomicroscopy. *Ophthalmol Clin N Amer* 1995;8:281-293.
  40. Tello CT, Ishikawa H, Rothman RF, Ritch R. Differential diagnosis of the angle-closure glaucomas. *Ophthalmol Clin N Amer* 2000;13:443-454.
  41. Gazzard G, Friedman DS, Devereux JG, Chew PT, Seah SK. A prospective ultrasound biomicroscopy evaluation of changes in anterior segment morphology after laser iridotomy in Asian eyes. *Ophthalmology* 2003;110:630-638.

42. Wang N, Wu H, Fan Z. Primary angle closure glaucoma in Chinese and Western populations. *Chinese Medical Journal* 2002;115:1706-1715.
43. Mandell MA, Pavlin CJ, Weisbrod DJ, Simpson ER. Anterior chamber depth in plateau iris syndrome and pupillary block as measured by ultrasound biomicroscopy. *Am J Ophthalmol* 2003;136:900-903.
44. Li PS, Lai JS, Lam DS. Anterior chamber depth in plateau iris syndrome and pupillary block as measured by ultrasound biomicroscopy. *Am J Ophthalmol* 2004;137:1169-1170.
45. He M, Foster PJ, Johnson GJ, Khaw PT. Angle-closure glaucoma in East Asian and European people. Different diseases? *Eye* 2006;20:3-12.
46. Garudadri CS, Chelerkar V, Nutheti R. An ultrasound biomicroscopic study of the anterior segment in Indian eyes with primary angle-closure glaucoma. *J Glaucoma* 2002;11:502-507.
47. Scheie HG. Width and pigmentation of the angle of the anterior chamber. A system of grading by gonioscopy. *Arch Ophthalmol* 1957;58:510-512.
48. Spaeth GL. The normal development of the human anterior chamber angle: a new system of descriptive grading. *Transactions of the Ophthalmological Societies of the United Kingdom* 1971;91:709-739.



Poule Helge Alsbirk (left) and George Spaeth (right).

# MANAGEMENT OF ACUTE ANGLE CLOSURE CRISIS

*Co-chairs:* Harry Quigley and Tetsua Yamamoto



Harry Quigley

## Defining acute angle closure

For acute angle closure attacks, the following features have been consistently used in recent publications:<sup>1</sup>

- Presence of at least two of the following symptoms: ocular or periocular pain, nausea and/or vomiting, an antecedent history of intermittent blurring of vision with haloes;
- Presenting intraocular pressure (IOP) of more than 21 mmHg (as measured by Goldmann applanation tonometry) and the presence of at least three of the following signs: conjunctival injection, corneal epithelial edema, mid-dilated unreactive pupil, and shallow anterior chamber.

## *Differential diagnosis of acute angle closure*<sup>2</sup>

- Primary acute angle closure
- Plateau iris syndrome (distinguished by failure of iridotomy to prevent recurrent attack)
- Secondary pupil block due to uveitis (characterized by seclused pupil and iris bombe)
- Lens-induced angle closure
  - Intumescent lens (phacomorphic)
  - Anterior lens subluxation
  - Trauma with dislocation of lens
- Malignant glaucoma
  - Idiopathic, unresponsive to iridotomy
  - Related to recent surgery
  - May occur in unoperated eye
- Retinopathy of prematurity
  - Persistent hyperplastic primary vitreous
- Conditions related to choroidal expansion
  - Drug-induced

*Angle Closure and Angle Closure Glaucoma, pp. 21-26*

*edited by Robert N. Weinreb*

© 2006 Kugler Publications, The Hague, The Netherlands

- Posterior scleritis
- Acquired immunodeficiency syndrome
- Vogt-Koyanagi-Harada Syndrome
- Panretinal photocoagulation
- Carcinoma, leukemia
- Arteriovenous fistulas: orbital or carotid cavernous fistula
- Neuropathia epidemica or mumps virus infection
- Secondary angle closure due to anterior neovascularization
- Open angles with acute IOP elevation masquerading as acute angle closure
  - Glaucomatocyclitic crisis
  - Steroid-induced glaucoma
  - Phacolytic glaucoma
  - Ghost cell glaucoma
  - Hemolytic glaucoma
  - Hemorrhagic glaucoma
  - Exfoliation glaucoma<sup>3</sup>

Examination techniques to detect mechanism of symptoms

- Visual acuity;
- Intraocular pressure measurement;
- Slit lamp examination;
- Gonioscopy (4-mirror indentation-type lens and/or one mirror Goldmann-type);
- Optic disc exam (without dilation);
- Fellow eye assessment to assure narrow angles in both eyes.

### Immediate management<sup>4</sup>

*a. Medical management:* by consensus, this should be tried first in order to lower IOP and to make the next step in therapy easier.

- Eyedrops, including beta blockers, alpha agonists, carbonic anhydrase inhibitors and pilocarpine;
- Oral or intravenous acetazolamide;
- Oral hyperosmotic agents (if safe for the patient);
- Intravenous hyperosmotic agents (if safe for the patient);
- Topical glycerin eyedrops to improve the view;
- Topical steroids.

*b. Peripheral iridoplasty<sup>5-8</sup>* (or pupilloplasty) may have a role in addition to, or in place of medical therapy to stop an acute attack.

*c. Paracentesis:* reserved for temporary lowering of IOP.<sup>9</sup>

## **Laser iridotomy**

### *a. Methods*

- Nd:YAG, argon/diode, or both in combination appropriate in various settings;
- Pilocarpine 30-60 minutes before laser, frequent (every one to two hours for the first day) steroid after laser, do not rush to do the laser immediately after the attack, and try not to complete the laser in a single session;
- Evidence favors initial laser iridotomy effectiveness.<sup>10</sup>

### *b. Iridotomy of fellow eye*

- Treatment of the fellow eye is effective.<sup>11-13</sup>

### *c. Long-term follow-up*

- Eyes should be assessed for degree of angle closure (at least by gonioscopy, perhaps by objective measures like UBM), to determine presence and extent of PAS, degree of cataract, as well as optic disc and visual field damage. This is an assessment of disease severity;
- IOP should be checked at intervals determined by the presence and extent of PAS during the first twelve months to detect asymptomatic rise in IOP.

## **Methods when laser iridotomy fails**

### *a. Waiting for medical IOP lowering and clearer cornea*

- If iridotomy is not completed, waiting for a short period (around 24 hours) to reduce inflammation with steroids and IOP (with Diamox, Mannitol or glycerol plus topic hypotensive medication) may allow the completion;
- Do not rush to next treatment, since this is the way to avoid endothelial problems.

### *b. Paracentesis*

- May also be used in combination with medical therapy as first line treatment, but not for all cases. In very wide pupils with extremely shallow anterior chambers the lens may be at risk. Certainly not for the inexperienced surgeon in spite of its simplicity;<sup>9</sup>
- The procedure may rapidly relieve pain, clear cornea, lower IOP, and allow completion of the laser procedures.

*c. Surgical iridectomy*

- When laser iridotomy fails or is not feasible, a surgical iridectomy is the established choice, provided there is some degree of pupillary block. It may be considered, thus, in case of inability to complete the iridotomy, corneal opacity, lack of space between iris and cornea, excess mydriasis, and ‘difficult irides’ (e.g., thick tissue without crypts).
- No differences in terms of visual acuity and of IOP have been observed between LI and iridectomy in a three-year RCT of unilateral AAC.<sup>14</sup>

*d. Iridoplasty*

- May break acute attack;
- Concerns about possible adverse outcomes including corneal decompensation.

*e. Mechanically opening the angle by pressing the cornea*<sup>15</sup>*f. Lens extraction*

- When there is a coincident cataract causing enough visual loss to deserve removal, phacoemulsification and IOL implantation is a surgical option that may resolve AAC cases refractory to LI and iridectomy;<sup>16</sup>
- Limited data on cataract surgery as initial treatment;
- If there is concurrent synechial closure, phacoemulsification may be combined with goniosynechialysis.<sup>17</sup> Results are encouraging (62% IOP reduction with average follow-up of one year);
- This approach may not be ideal in cases of plateau iris, because iridociliary apposition persists after cataract removal.<sup>18</sup>

*g. Trabeculectomy*

- Success in acutely inflamed eyes poor: IOP control was obtained in 56.2% of patients, qualified success in 9.4% and failure in 34.4%.<sup>19</sup>

*h. Malignant glaucoma (uniformly shallow AC and generally high IOP)*

- Differential diagnosis includes aqueous misdirection and shallow anterior choroidal effusions.
- UBM to exclude choroidal effusions may be appropriate;
- Treat effusions with IOP- lowering with aqueous suppressants and possibly hyperosmotics, steroids and atropine. Drainage of choroidals may be necessary if there is no response to medical treatment.

For aqueous misdirection:

- Medical treatment includes mydriatics, aqueous suppressants and hyperosmotics. Acetazolamide has a relevant role, and miotics are contraindicated;
- Nd:YAG to disrupt the hyaloid face through pupil or iridectomy (in pseudophakic or aphakic eyes);
- Definitive resolution can be obtained by vitrectomy;<sup>20-22</sup>
- There is weak evidence that it may be preferable to accompany vitrectomy with lens extraction, and with primary posterior capsulectomy.<sup>23</sup>

### Consensus Statements

- Laser iridotomy should be performed as soon as feasible in the affected eye(s), and should also be performed as soon as possible in the contralateral eye.
- Medical management is the recommended first step in treating acute angle closure, but the results of studies comparing this to immediate laser surgery are not yet available.
- Laser iridoplasty can be effective at breaking acute attacks and should be considered if an attack cannot be broken by other means.
- Paracentesis should be reserved for cases where other approaches have failed.
- Primary cataract extraction may be a treatment option, but data supporting its use are limited.

### References

1. Aung T, Friedman DS, Chew PT, Ang LP, Gazzard G, Lai YF, Yip L, Lai H, Quigley H, Seah SK. Long-term outcomes in asians after acute primary angle closure. *Ophthalmology* 2004;111:1464-1469.
2. Tello C, Rothman R, Ishikawa H, Ritch R. Differential diagnosis of angle closure glaucoma. *Ophthalmol Clin North Amer* 2000;13:443-453.
3. Gillies WE, Brooks AMV: The presentation of acute glaucoma in pseudoexfoliation of the lens capsule. *Aust NZ J Ophthalmol* 1988;16:101-106.
4. Chong YF, Irfan S, Menege MS. AACG: an evaluation of a protocol for acute treatment. *Eye* 1999;13:613-616.
5. Lam DS, Lai JS, Tham CC, Chua JK, Poon AS. Argon laser peripheral iridoplasty versus conventional systemic medical therapy in treatment of acute primary angle-closure glaucoma: a prospective, randomized, controlled trial. *Ophthalmology* 2002;109:1591-1596.
6. Lai JS, Tham CC, Chua JK, Poon AS, Chan JC, Lam SW, Lam DS. To compare argon laser peripheral iridoplasty (ALPI) against systemic medications in treatment of acute primary angle-closure: mid-term results. *Eye* 2006;20:309-314.
7. Lai JS, Tham CC, et al. To compare argon laser peripheral iridoplasty (ALPI) against systemic medications in treatment of acute primary angle-closure: mid-term results. *Eye* 2006;20:309-314.
8. Quaranta L, Bettelli S, et al. Argon laser iridoplasty as primary treatment for acute angle



- closure glaucoma: a prospective clinical study. *Acta Ophthalmol Scand Suppl* 2002;236:16-17.
9. Lam DS, Chua JK, Tham CC, Lai JS. Efficacy and safety of immediate anterior chamber paracentesis in the treatment of acute primary angle-closure glaucoma: a pilot study. *Ophthalmology* 2002;109:64-70.
  10. Saw SM, Gazzard G, Friedman DS. Interventions for angle-closure glaucoma: an evidence-based update. *Ophthalmology* 2003;110:1869-1878.
  11. Friedman DS, Chew PTK, Gazzard G, Ang LPK, Lai YF, Seah SKL, Quigley HA, Aung T. Long-term outcomes in fellow eyes after acute primary angle closure in the contralateral eye. *Ophthalmology* (submitted for publication).
  12. Aung T, Ang LP, Chan SP, Chew PT. Acute primary angle-closure: long term intraocular pressure outcome in Asian eyes. *Am J Ophthalmol* 2001;131:7-12.
  13. Choong YF, Irfan S, Menage MJ. Acute angle closure glaucoma: an evaluation of a protocol for acute treatment. *Eye* 1999;13:613-616.
  14. Fleck BW, Wright E, Fairley EA. A randomized prospective comparison of operative peripheral iridectomy and Nd:YAG laser iridotomy treatment of acute angle closure glaucoma: 3 year visual acuity and intraocular pressure control outcome. *Br J Ophthalmol* 1997;81:884-888.
  15. Forbes M. Indentation gonioscopy and efficacy of iridectomy in angle-closure glaucoma. *Trans Am Ophthalmol Soc* 1974;72:488-515.
  16. Harasymowycz PJ, Papamatheakis DG, Ahmed I, Assalian A, Lesk M, Al-Zafiri Y, Kranemann C, Hutnik C. Phacoemulsification and goniosynechialysis in the management of unresponsive primary angle closure. *J Glaucoma* 2005;14:186-189.
  17. Teekhasaene C, Ritch R. Combined phacoemulsification and goniosynechialysis for uncontrolled chronic angle-closure glaucoma after acute angle-closure glaucoma. *Ophthalmology* 1999;106:669-674.
  18. Tran HV, Liebmann JM, Ritch R. Iridociliary apposition in plateau iris syndrome persists after cataract extraction. *Am J Ophthalmol* 2003;135:40-43.
  19. Aung T, Tow SL, Yap EY, Chan SP, Seah SK. Trabeculectomy for acute primary angle closure. *Ophthalmology* 2000;107:1298-302.
  20. Harbour JW, Rubsamen PE, Palmberg P. Pars plana vitrectomy in the management of phakic and pseudophakic malignant glaucoma. *Arch Ophthalmol* 1996;114:1073-1078.
  21. Byrnes GA, Leen MM, Wong TP, Benson WE. Vitrectomy for ciliary block (malignant) glaucoma. *Ophthalmology* 1995;102:1308-1311.
  22. Tsai JC, Barton KA, Miller MH, Khaw PT, Hitchings RA. Surgical results in malignant glaucoma refractory to medical or laser therapy. *Eye* 1997;11:677-681.
  23. Zhi ZM, Lim ASM, Wong TY. A pilot study of lens extraction in the management of acute primary angle-closure glaucoma. *Am J Ophthalmol* 2003;135:534-536.

# SURGICAL MANAGEMENT OF PRIMARY ANGLE CLOSURE GLAUCOMA

*Co-chairs:* Tin Aung, Prin RojanaPongpun and  
John Salmon



Tin Aung

## Introduction

Unlike POAG, there have been few published studies and trials in the surgical management of PACG. Consequently, many of the recommendations in this document are largely based on consensus.

## Assessment of PACG eyes

There are several issues to consider in the assessment of PACG patients before surgery is contemplated. The main issues are summarized below.

### *Mechanism*

The planning of surgical management of PACG requires an understanding of the underlying pathophysiological mechanisms and natural history of disease. This has been discussed in the Epidemiology and Mechanisms section and will only be summarized briefly. By definition, angle closure results from obstruction to the outflow of aqueous from the anterior chamber of the eye by the presence of iris overlying the trabecular meshwork in the iridocorneal angle. The most widely-used classification of mechanism is the four-point scheme which identifies obstructions to aqueous flow at progressively more posterior levels.<sup>1</sup>

- Pupil-block;
- Plateau iris/Ciliary body;
- Lens-induced;
- Causes behind the lens.

Of these, pupillary block is the main underlying mechanism causing angle closure.<sup>1-4</sup> The non-pupillary block mechanisms that are also important in PACG

*Angle Closure and Angle Closure Glaucoma, pp. 27-35*

*edited by Robert N. Weinreb*

© 2006 Kugler Publications, The Hague, The Netherlands

include angle crowding, such as from plateau iris or the lens, and damaged trabecular function.<sup>5-9</sup> Choice of management is also dependent on the stage of the disease, specifically whether there is evidence of advanced trabecular damage (advanced PAS or high IOP) or the presence and severity of glaucomatous optic neuropathy.

#### *Exclusion of other mechanisms/secondary angle closure*

There is need to exclude other secondary angle closure glaucomas (such as uveitis, neovascular glaucoma and subluxated lenses).

#### *Gonioscopy to evaluate the extent of PAS*

The extent of PAS has been found to correlate with angle width, the level of IOP and extent of disc damage.<sup>10-11</sup> Eyes with greater amounts of PAS are more likely to be inadequately treated with medications/laser and to require surgery.<sup>12-20</sup> It has been suggested that eyes with PAS of more than two quadrants will particularly be at risk of requiring surgery.<sup>13</sup>

#### *Optic disc damage and visual field loss*

Similarly, it is likely that PACG eyes with greater optic disc damage and visual field loss are more likely to require surgery.

#### *IOP and the number of medications*

The level of IOP without treatment, and the number and type of glaucoma medications being administered should be considered. Use of topical medications like miotics should preferably be discontinued before surgery.

#### *Degree of cataract*

The degree of cataract and visual acuity is another important consideration for surgery (see below).

### **Aims of surgical treatment**

- Reduce the risk of optic nerve damage;
- Prevent an acute attack of angle closure (more for laser PI).

Although prevention of progressive angle closure is desirable, it is not clear at the current time how this can be affected.

## Indications for surgery in PACG

The indications for surgery in PACG are as for POAG, namely:

- IOP not reaching target level;
- Progression of optic nerve/visual field damage in spite of medical therapy;
- Poor compliance or intolerance to medical treatment;
- Poorly controlled glaucoma at the time of planned cataract surgery.

An added indication for surgery in PACG may be progression of angle closure and PAS. Progression of PAS/angle closure is difficult to detect due to inter and intra-observer variation. This rarely occurs as an isolated indication as the IOP tends to increase as the angle closes.

## Timing of surgery: should laser PI be performed in all cases, or should some cases have primary incisional surgery?

The conventional management of PACG is to perform laser peripheral iridotomy (LPI)<sup>21-25</sup> to relieve pupillary block. By performing LPI, it is hoped that the angle will widen, IOP will decrease and that LPI will serve as prophylaxis against an acute episode of angle closure. The procedure can be performed quickly on an outpatient basis without the risks of incisional surgery such as endophthalmitis.

However, LPI may not reduce IOP sufficiently in all cases. In retrospective chart reviews, the majority of PACG eyes treated by LPI required further medication to control IOP, and a significant percentage went on to require surgery (although the exact indications for surgery were not standardized).<sup>13-17</sup>

It is difficult to predict on presentation which eyes with PACG will need subsequent surgery after LPI. In one study, IOP control in a cohort of PACG subjects was more likely to be successful after LPI in eyes with less than 180° of PAS compared with eyes with more extensive PAS.<sup>14</sup> It is more likely that eyes with advanced disc damage and visual field loss and extensive PAS will require additional surgical treatment after laser PI.<sup>12-20</sup>

Another consideration is the presence of significant cataract. Eyes with visually disturbing cataract are often considered for primary cataract surgery (with or without trabeculectomy) instead of performing LPI first.

Patients who are uncooperative for laser or with poor corneal clarity (for LPI) may be another group to be considered for primary surgery.

## Surgical options and considerations

There is at present no consensus on the best approach to the surgical management of PACG. Once LPI is performed and IOP is still not optimally controlled,

the surgical options for PACG are diverse. These include filtering surgery alone, lens extraction alone, combined lens extraction and filtering surgery, angle widening procedures such as goniosynechialysis, and an angle widening procedure combined with lens extraction. Other considerations include the method of lens extraction, be it phacoemulsification or ECCE, the use of antimetabolites, and the number and choice of surgical sites in filtering surgery. Randomized controlled trials are necessary to evaluate these types of surgery in PACG.

### **Trabeculectomy**

The indications for trabeculectomy in PACG are the same as in POAG. These include inadequate control of IOP (despite LPI), continuing optic disc/visual field damage and intolerance to medical therapy. The indications for the use of anti-scarring agents are also similar to that of POAG, namely eyes at high risk of failure of surgery (such as those with previous failed trabeculectomy), those with advanced disease (extensive PAS, optic nerve damage and visual field loss) and those on multiple medications. In many centers, anti-scarring agents are used routinely for all trabeculectomies.

There have been no randomized controlled trials published to date for trabeculectomy in PACG. A retrospective study from India showed that trabeculectomy without antimetabolite use appears to be efficacious in lowering IOP and in visual field preservation over a period of ten years in patients with PACG, with similar outcomes as POAG. About a third of PACG cases had a two-line decrease in visual acuity due to the development of a cataract.<sup>26</sup>

In eyes with PACG, malignant glaucoma is commonly cited as a possible complication following trabeculectomy. However, this was not observed in a study by Watson *et al.* conducted in the UK, which showed similar complication rates to POAG and angle closure eyes.<sup>27</sup>

### **Lens extraction alone**

It is believed that the size and position of the lens plays a major role in the pathogenesis of PACG.<sup>1,5</sup> With aging, there is an increase in the thickness of the lens and a more relatively anterior lens position. In eyes which are hyperopic with small anterior segments, this effect is likely to be accentuated and the result is crowding in the angles and a greater predisposition to pupillary block.<sup>28-29</sup>

Lens extraction with posterior chamber intraocular lens implantation has been found to result in satisfactory IOP control postoperatively in eyes with PACG.<sup>30-34</sup> It is postulated that the deepening of the anterior chamber results in a reduction of angle crowding and relief of relative pupil block. A study employing Scheimpflug video photography to study the angle, showed that the width and depth of the angle in eyes with PACG increased significantly after

phacoemulsification, and became similar to that in eyes with open angles.<sup>35</sup> In addition, lens extraction may lower IOP<sup>36</sup> and reduce the likelihood of progressive angle closure and a chronic rise in IOP.

Problems encountered after cataract surgery in patients with PACG include significant inflammation and transient elevations in IOP in the immediate post-operative period.<sup>30-31</sup> This IOP spike may be dangerous for eyes with advanced visual field loss. Furthermore, many eyes require a second surgery later to control IOP. In a comparative non-randomized study of lens extraction against filtering surgery for angle closure glaucoma, Gunning & Greve found that filtering surgery yielded better long-term glaucoma control than cataract surgery alone (lower IOP and less ocular hypotensive medication) but was accompanied by more complications and deterioration in visual function due to subsequent development of cataract.<sup>33</sup> Lens removal also does not remove the risk of angle closure in eyes with plateau iris syndrome.

Cataract surgery in PACG eyes (especially those with previous APAC) is technically difficult. The anterior chamber is usually shallow, the lens often bulky and the pupil is frequently small from miotic treatment or ischaemic iris atrophy. Excessive curvature of the anterior capsule may also predispose to tears. Iris ischemia from a previous acute episode may render the iris flaccid, which together with a small pupil, may make the iris more susceptible to trauma during surgery. Hooks can be used to deal with small pupils. Corneal decompensation is another potential long-term complication. For cases of previous APAC, the corneal endothelium already at risk of damage from the acute episode may undergo further injury from phacoemulsification leading to higher risk of decompensation. PACG eyes may also be at higher risk of lens subluxation or zonular weakness as well as aqueous misdirection during and after surgery.

### **Combined cataract and trabeculectomy surgery**

Combined phacoemulsification, intraocular lens implantation and trabeculectomy is another option in the surgical management of PACG. This procedure offers the advantages of visual rehabilitation after cataract extraction, prevention of IOP spikes in the immediate post-operative period, and widening of the angle after lens removal with improved IOP control. The combined procedure exposes the patient to a single surgical experience, saving on the 'opportunity cost' of operating room time. The use of adjunctive antimetabolites in combined surgery has further increased the surgical options available.

However, data are limited on the outcome of such surgery for PACG. A retrospective study from Singapore showed that combined phacoemulsification with posterior chamber intraocular lens implantation and trabeculectomy was associated with good IOP control and visual outcome in patients with PACG. There were no intraoperative complications in this series and the incidence of

post-operative complications was also low.<sup>37</sup> Another study found that the complication rates of phacotrabeculectomy were similar in PACG and POAG patients.<sup>38</sup>

### **Other forms of surgery**

#### *Surgical iridectomy alone*

Surgical iridectomy alone has a limited role in the current management of PACG. It may be performed when lasers are not available or for patients who are uncooperative/unsuitable for LPI.

#### *Goniosynechialysis with cataract extraction*

Goniosynechialysis, an angle-widening procedure, is another surgical option for treatment of PACG.<sup>39</sup> It has also been combined with cataract extraction in eyes with previous acute angle closure.<sup>40</sup> In this procedure, PAS are physically stripped from the angle wall, opening the angle and restoring trabecular function. There are limited data on the long-term effectiveness of this procedure for PACG. It is thought that goniosynechialysis may more likely be successful if the synechiae have been present for less than one year.

#### *Glaucoma implants*

Glaucoma drainage implant surgery is usually performed in eyes with refractory glaucoma with high risk of failure of conventional trabeculectomy. In retrospective studies, drainage implants have been demonstrated to work in PACG eyes with previous failed trabeculectomy,<sup>41</sup> as well as when combined with lens extraction.<sup>42</sup>

#### *Cyclodestructive procedures*

Cyclodestructive procedures are used for PACG eyes with end stage disease without visual potential, and are symptomatic due to high IOP. They are not recommended as primary procedures.

#### **Issues requiring further attention**

As there is a paucity of studies on the surgical management of PACG, there is a need for:

- Long term data on the various forms of surgery for PACG;
- Randomized controlled trials in particular to investigate the role of lens extraction and goniosynechialysis in PACG.

### Consensus Statements

- Laser peripheral iridotomy is recommended as the primary procedure in eyes with PACG.

*Comment:* LPI can be performed easily on an outpatient basis and patients can then be monitored for response to treatment. This will allow time to undertake elective surgery in those with uncontrolled IOP, those with advanced disease or with co-existing cataract. LPI also serves as prophylaxis against acute angle closure.

- There is lack of evidence for recommending primary incisional surgery (without laser PI) in eyes with PACG.
- Trabeculectomy may be performed to lower IOP in eyes with chronic PAC (G) insufficiently responsive to laser or medical therapy.
- There is insufficient evidence for deciding which cases with PACG should undergo cataract surgery alone (without trabeculectomy).

*Comment:* Cataract surgery alone may be considered in eyes with mild degree of angle closure (less than 180 degrees of PAS), mild optic nerve/visual field damage or those that are not on maximal tolerated medical therapy.

- There is lack of evidence for recommending lens extraction alone in eyes with more advanced PACG.

*Comment:* Published studies to date have been non-randomized with small sample sizes and short follow up.

- Combined cataract and glaucoma surgery in certain eyes may be useful to control IOP and restore vision.

*Comment:* There is limited published evidence about the effectiveness of combined cataract extraction and trabeculectomy in eyes with PACG. There is a need for studies comparing this form of surgery with separately staged cataract extraction and trabeculectomy

- There is limited evidence about the effectiveness of goniosynechialysis in the management of PACG.

### References

1. Ritch R, Lowe RF. Angle closure glaucoma. In: Ritch R, Shields MB, Krupin T (eds). The Glaucomas. St Louis: CV Mosby, 1996:801.
2. Wang N, Wu Z, Liu H. Mechanism and etiology of primary chronic angle closure glaucoma. Yen KO Hsueh Pao 1994;10:186-192.
3. Kim YY, Jung HR. Clarifying the nomenclature for primary angle-closure glaucoma. Surv Ophthalmol 1997;42:125-136.
4. Gazzard G, Friedman DS, Devereux JG, Chew PT, Seah SK. A prospective ultrasound biomicroscopy evaluation of changes in anterior segment morphology after laser iridotomy in Asian eyes. Ophthalmology 2003;110:630-638.
5. Hung PT, Chou LH. Provocation and mechanism of angle-closure glaucoma after iridectomy. Arch Ophthalmol 1979;97:1862-1864.
6. Ritch R, Lowe RF, Reyes A. Therapeutic overview of angle-closure glaucoma. In: Ritch R, Shields MB, Krupin T (eds). The glaucomas. St Louis: CV Mosby, 1989:858.




7. Li PS, Lai JS, Lam DS. Anterior chamber depth in plateau iris syndrome and papillary block as measured by ultrasound biomicroscopy. *Am J Ophthalmol* 2004;137:1169-1170.
8. He M, Foster PJ, Johnson GJ, Khaw PT. Angle-closure glaucoma in East Asian and European people. Different diseases? *Eye* 2006;20:3-12.
9. Sihota R, Lakshmaiah NC, Walia KB, et al. The trabecular meshwork in acute and chronic angle closure glaucoma. *Indian J Ophthalmol* 2001;49:255-9.
10. Foster PJ, Machin D, Wong TY, et al. Determinants of intraocular pressure and its association with glaucomatous optic neuropathy in Chinese Singaporeans: the Tanjong Pagar Study. *Invest Ophthalmol Vis Sci* 2003;44:3885-3891.
11. Aung T, Lim MCC, Chan YH, Rojanapongpun P, Chew PT, EXACT Study Group. Configuration of the Drainage Angle, Intraocular Pressure and Optic Disc Cupping in Subjects with Chronic Angle Closure Glaucoma. *Ophthalmology* 2005;112:28-32.
12. Gelber EC, Anderson DR. Surgical decisions in chronic angle-closure glaucoma. *Arch Ophthalmol* 1976;94:1481-1484.
13. Playfair TJ, Watson PG. Management of chronic or intermittent primary angle-closure glaucoma: a long-term follow-up of the results of peripheral iridectomy used as an initial procedure. *Br J Ophthalmol* 1979;63:23-28.
14. Hoskins HD Jr, Kass MA. Becker-Shaffer's Diagnosis and Therapy of the Glaucomas: Angle-closure Glaucoma with Pupillary Block. St Louis: CV Mosby, 1989:208-237.
15. Shields MB. Textbook of Glaucoma: Primary angle closure glaucoma. Baltimore: Williams & Wilkins, 1992:198-219.
16. Salmon JF. Long-term intraocular pressure control after Nd-YAG laser iridotomy in chronic angle-closure glaucoma. *J Glaucoma* 1993;2:291-296.
17. Yamamoto T, Shirato S, Kitazawa Y. Treatment of primary angle-closure glaucoma by argon laser iridotomy: a long-term follow-up. *Jpn J Ophthalmol* 1985;29:1-12.
18. Alsagoff Z, Aung T, Ang LPK, Chew PTK. Long-term clinical course of primary angle-closure glaucoma in an Asian population. *Ophthalmology* 2000;107:2300-2304.
19. Rosman M, Aung T, Ang LPK, Chew PTK, Liebmann J, Ritch R. Chronic Angle-Closure with Glaucomatous Damage: Long-term Clinical Course in a North American population and comparison with an Asian Population. *Ophthalmology* 2002;109:2227-2231.
20. Nolan WP, Foster PJ, Devereux JG, et al. YAG laser iridotomy treatment for primary angle closure in east Asian eyes. *Br J Ophthalmol* 2000;84:1255-1259.
21. Ritch R. The treatment of chronic angle-closure glaucoma. *Ann Ophthalmol* 1981;13:21-23.
22. Quigley HA. Long-term follow-up of laser iridotomy. *Ophthalmology* 1981;88:218-224.
23. Robin AL, Pollack IP. Argon laser peripheral iridotomies in the treatment of primary angle-closure glaucoma: long-term follow-up. *Arch Ophthalmol* 1982;100:919-923.
24. Gieser DK, Wilensky JT. Laser iridectomy in the management of chronic angle-closure glaucoma. *Am J Ophthalmol* 1984;98:446-450.
25. Schwartz LW, Moster MR, Spaeth GL, Wilson RP, Poryzees E. Neodymium-YAG laser iridectomies in glaucoma associated with closed or occludable angles. *Am J Ophthalmol* 1986;102:41-44.
26. Sihota R, Gupta V, Agarwal HC. Long-term evaluation of trabeculectomy in primary open angle glaucoma and chronic primary angle closure glaucoma in an Asian population. *Clin Exp Ophthalmol* 2004;32:23-28.
27. Watson PG, Barnett F. Effectiveness of trabeculectomy in glaucoma. *Am J Ophthalmol* 1975;79:831-845.
28. Salmon, HF, Swanevelde, SA, Donald, MA. The dimensions of eyes with chronic angle-closure glaucoma. *J Glaucoma* 1994;3:237.
29. Ritch R. Glaucomas secondary to lens intumescence and dislocation. In: Ritch R, Shields MV (eds). *The Secondary Glaucomas*, St Louis, MO, CV Mosby, 1982;131-149.
30. Wishart PK, Atkinson PL. Extracapsular cataract extraction and posterior chamber lens implantation in patients with primary chronic angle-closure glaucoma: effect on intraocular pressure control. *Eye* 1989;3:706-712.

31. Greve EL. Primary angle closure glaucoma: Extracapsular cataract extraction or filtering procedure? *International Ophthalmology* 1988;12:157-162.
32. Acton J, Salmon JF, Scholtz R. Extracapsular cataract extraction with posterior chamber lens implantation in primary angle-closure glaucoma. *J Cataract Refract Surg* 1997;23:930-934.
33. Gunning, FP, Greve EL. Lens extraction for uncontrolled glaucoma. *J Cataract Refract Surg* 1998;24:1347-1356.
34. Roberts TV, Francis IC, Lertusumitkul S, et al. Primary phacoemulsification for uncontrolled angle-closure glaucoma. *J Cataract Refract Surg* 2000;26:1012-1016.
35. Hayashi K, Hayashi H, Nakao F, Hayashi F. Changes in anterior chamber angle width and depth after intraocular lens implantation in eyes with glaucoma. *Ophthalmology* 2000;107:698-703.
36. Obstbaum SA. Cataract surgery and its effect on intraocular pressure. *J Cataract Refract Surg* 1999;25:877.
37. Tow SLC, Aung T, Oen FTS, Seah SKL. Combined phacoemulsification, intraocular lens implantation and trabeculectomy in Asian patients with chronic angle closure glaucoma. *Int Ophthalmol* 2001;24:283-289.
38. Lai JS, Tham CC, Chan JC, Lam DS. Phacotrabeculectomy in treatment of primary angle-closure glaucoma and primary open-angle glaucoma. *Jpn J Ophthalmol* 2004;48:408-411.
39. Campbell DG, Vela A. Modern goniosynechialysis for the treatment of synechial angle-closure glaucoma. *Ophthalmology* 1984;91:1052-1060.
40. Teekhasaene C, Ritch R. Combined phacoemulsification and goniosynechialysis for uncontrolled chronic angle-closure glaucoma after acute angle-closure glaucoma. *Ophthalmology* 1999;106:669-675.
41. Seah SKL, Gazzard G, Aung T. Intermediate-term Outcome of Baerveldt Glaucoma Implants in Asian Eyes. *Ophthalmology* 2003;110:888-894.
42. Chung AN, Aung T, Wang JC, Chew PTK. Surgical outcomes of combined phacoemulsification and glaucoma drainage implant surgery for Asian patients with refractory glaucoma and cataract. *Am J Ophthalmol* 2004;137:294-300.



Jeffrey Liebmann (podium), Robert N. Weinreb, David S. Friedman, Paul Foster, Aung Tin (left to right).



Robert Ritch providing a historical perspective.



Robert Ritch discussing gonioscopy.

# LASER AND MEDICAL TREATMENT OF PRIMARY ANGLE CLOSURE GLAUCOMA

*Co-chairs:* Robert Ritch, Winnie Nolan and Dennis Lam



Robert Ritch

## Introduction

The aim of this section is to discuss the current practice for non-surgical management of PACG. A summary of the literature and strength of evidence for the interventions of laser iridotomy, argon laser peripheral iridoplasty and medical treatment will be given.

## Laser Peripheral Iridotomy (LPI)

Laser peripheral iridotomy (LPI) replaced surgical iridectomy as first-line treatment of PACG in the late 1970s with the advent of argon and then Nd:YAG laser technology. The Nd:YAG laser was shown in prospective studies to be as effective as surgical iridectomy and argon laser iridotomy.<sup>1-3</sup> It has the advantages of using less total energy than argon laser and is theoretically less likely to cause damage to the lens and retina.

### *Mechanism of action*

Laser iridotomy alleviates pupillary block by allowing aqueous to bypass the pupil. The pressure differential between anterior and posterior chambers is eliminated; the iris loses its convex configuration and falls away from the trabecular meshwork, resulting in the partial or complete opening of the angle.<sup>4</sup>

### *Indications for LPI*

*Prevention of acute angle closure:* Lowe and Snow reported that iridectomy was effective in preventing a subsequent episode of angle closure in fellow eyes of cases with acute angle closure. Left untreated these eyes had 50% risk of an attack of angle closure over five years.<sup>5,6</sup> Fellow eyes of PAC/PACG affected

eyes should be treated with LPI with the aim of the above points. The exception to this is in cases where the fellow eye is pseudophakic.

*Long-term IOP control:* In patients presenting with PAC/PACG who have elevated IOP one of the aims of LPI treatment is to try and achieve target IOP levels by treating the reversible component of the disease, *i.e.*, appositional angle closure.

*Prevention of PAS formation and progressive glaucomatous optic nerve damage:* By eliminating appositional closure due to pupillary block and thereby removing the principal causal mechanism underlying PAS development. And by relieving appositional closure, therefore theoretically either lowering co-existing raised IOP, or preventing future IOP rises which lead on to development or progression of glaucomatous optic neuropathy.

### *Techniques for performing LPI*

*Optimal size and location of LPI:* While some recommend that the LPI should be positioned in the peripheral one third of the iris between 11:00 and 1:00 o'clock, in order to minimize visual symptoms which patients may suffer if the LPI is placed at the lid margin or in the interpalpebral region, others routinely place the LPI at the 3 and 9 o'clock positions.<sup>7</sup> Where iris crypts are present, the iris will be thinner and these sites, if in a suitable position, should be used for LPI.

Fleck calculated that an iridotomy should be a minimum size of 15 microns in order to prevent pupillary block but suggested aiming for a size of 150-200 microns.<sup>8</sup> One of the factors incorporated into the model he used for the calculations was the iris thickness. As brown Asian irides are thicker and more bulky than blue ones they probably require a larger iridotomy.

### *LPI methods*

#### Argon LPI

Argon laser began to replace surgical iridectomy as a safer, non-invasive method of making an iridotomy in the late 1970s. It was demonstrated to be safe and effective,<sup>9</sup> but required melanin for tissue absorption of the energy, making it less easy to penetrate lightly pigmented blue irides.

#### Nd:YAG LPI

The Nd:YAG laser replaced argon as the most common means of performing LPI in the late 1980s. The Q-switched mode of the Nd:YAG laser causes photodisruption of tissues by the formation of a high energy ionic plasma at the

location of focus of very intense energy. It has the advantage of not requiring the presence of melanin pigment for iris absorption. The overall energy required to produce an iridotomy is lower than that required with argon laser. Nd:YAG lasers are usually smaller and portable which can be useful where treatment of patients in the community is necessary. The Nd:YAG LPI is the method of choice for Caucasian angle closure patients with blue or light brown irides.

### Sequential argon / Nd:YAG LPI

In patients with brown irides, large amounts of energy may be required to achieve a patent PI when using the Nd:YAG laser. This of particular relevance in Asian and African populations, but also applies to some Caucasian individuals. Argon laser pre-treatment to thin the iris results in the need for less energy with the Nd:YAG laser, which is then used to penetrate the iris and create an iridotomy.<sup>10,11</sup> The coagulative effect of the argon laser reduces the risk of haemorrhage from the iridotomy site. Frequency-doubling continuous wave Nd:YAG lasers can be used for the same purpose as the argon laser.

### *Guidelines for performing LPI*

- Patients presenting with newly diagnosed PAC or PACG with markedly elevated IOP should be treated with topical and systemic medications to achieve a safe IOP level (< 30 mmHg) prior to undergoing LPI;
- Pre-treat the eye with one drop of Pilocarpine 2 to constrict the pupil and use an alpha-agonist (brimonidine or apraclonidine) before and after laser treatment to minimize the risk of post laser IOP spikes;<sup>12</sup>
- Topical anesthesia;
- Lens: Abraham lens or Wise lens with coupling fluid.

### *Nd:YAG laser PI (suggested settings)*

Check that defocus is set to zero. Some surgeons start with relatively low power (1-3 mJ) to thin the iris, and others start with higher power (5-8 mJ) to quickly penetrate the iris. A gush of pigment from the posterior chamber signals patency of the iridotomy. Once a hole has been made in the iris, it should be enlarged horizontally to achieve an adequate size iridotomy. (If possible the energy should be lowered for enlarging the iridotomy).

### *Sequential argon / Nd:YAG PI (suggested settings)*

#### Argon laser settings

**Stage 1:** (optional): 50 micron spot size 100mW 0.05 seconds duration. Thirty shots in rosette pattern to thin the iris. This helps avoid large, adherent bubbles with higher power.



**Stage 2:** Increase power to 750Mw and duration to 0.1s10-15 shots (more if not employing stage 1) to form deep central crater.

Nd:YAG laser settings

1- 3 mJ and increase to power required to penetrate iris in argon laser pre-treated area. Enlarge as for Nd:YAG PI.

- Following LPI administer alpha-agonist. Alternatively oral acetazolamide can be given in cases where there is concern of post-laser IOP spike, *e.g.*, in cases with raised IOP or advanced PACG;
- Check IOP 45-60 minutes after LPI;
- Post-laser treatment: Topical steroids should be administered to reduce inflammation and tapered according to the clinical response.

## Complications of LPI

*Early / immediate*

### Iris

- Iris hemorrhage from LPI site;
- Bleeding from the iris occurs during the procedure when iris vessels are hit by the Nd:YAG laser. Pressure on the globe from the laser lens will usually stop the bleeding.

### Cornea

Direct injury to the corneal epithelium or endothelium was reported in the past with argon laser when high energy was used to create iridotomies.<sup>13</sup> A more recent publication in which specular microscopy was used to examine the corneal endothelium following Nd:YAG laser procedures (including iridotomies), demonstrated that dark areas appeared in the endothelium and were related to the amount of Nd:YAG energy used. However, at six months post-iridotomy there was no statistically significant loss of corneal endothelial cells.<sup>14</sup>

### Anterior lens capsule

This rare complication of LPI can be avoided by placing the iridotomy in the peripheral iris away from the lens and by ensuring that the laser defocus is set to zero before starting treatment.

## **IOP Elevation**

The incidence of acute IOP rise following LPI is low due to the routine pre-treatment of eyes with topical alpha-agonists.<sup>15</sup> The patients in whom an IOP spike is more likely to occur, are those with advanced PACG and extensive synechial closure of the angle. The small amount of trabecular meshwork which is not closed by PAS is likely to have compromised outflow function and becomes blocked by the iris pigment and tissue generated by the PI. The result is an acute rise in IOP. A course of oral acetazolamide starting immediately following LPI and continued for two to three days may be considered in patients with advanced PACG undergoing LPI.

Sustained rises in IOP can occur following LPI. These patients need to be monitored closely and treated with topical and systemic IOP-lowering medications. The use of topical steroids may be a factor contributing to sustained elevation of IOP post-LPI. Topical non-steroidal anti-inflammatory agents can be used as an alternative to steroids in these patients. Excessive anterior chamber inflammation post-laser may be more common in people with thick, dark irides, e.g., Asians.

### *Late complications of LPI*

#### **Posterior synechiae**

The development of posterior synechiae following LPI can result in a permanently miotic pupil. Possible factors which may contribute to posterior synechiae formation include increased contact between the posterior iris and the anterior lens surface after LPI, the use of miotic agents, and anterior chamber inflammation.

#### **Accelerated cataract formation (*possible late complication*)**

There is concern that LPI may stimulate cataract formation or accelerate progression of existing lens opacities. A recent publication reports progression of pre-existing posterior subcapsular lens opacities in fellow eyes treated with LPI.<sup>16</sup> There is no control group to compare the findings with and there may be other factors present (underlying PAC, topical medication use) contributing to these findings. This potential complication is of more concern when considering prophylactic LPI for subjects with asymptomatic iridotrabecular contact. The risk of cataract development in subjects with established PAC and PACG is outweighed by the benefits of LPI.



## Clinical outcomes of LPI

### *Intraocular pressure*

The effectiveness of LPI can be measured in terms of the number of eyes or subjects in whom satisfactory intraocular pressure control is achieved and maintained following treatment, and by how many cases need additional medications or glaucoma surgery to achieve IOP control. Published figures for the proportion of LPI treated cases of PACG that achieve adequate IOP control vary from 51% with medication (South Africa) to 55% without medication (Mongolia).<sup>17,18</sup> Case definitions and target IOP levels are not consistent across these different studies.

A retrospective analysis of clinical outcomes was undertaken using data from North American and Singaporean patients with PACG (presence of glaucomatous optic neuropathy) who had been treated with LPI.<sup>19</sup> One hundred percent of the North American group and 94% of the Singaporean group required further treatment to control IOP following LPI. Glaucoma filtering surgery was necessary in 31.3% of the Americans and 53% of the Singaporeans.

A relationship between the stage of the angle closure process and IOP control following LPI has now been shown in a number of studies. Quigley found no association between pre-laser examination factors and outcome of iridotomy,<sup>9</sup> but a number of studies in Asian populations have demonstrated that LPI is less likely to control IOP in eyes with  $\geq 180^\circ$  of synechial angle closure.<sup>17,18,20,21</sup> The poor outcomes of LPI in Singaporean and American PACG patients add support to the belief that the more advanced the disease the less effective PI will be in controlling IOP. A study in Mongolia found that the degree of glaucomatous optic neuropathy as measured by cup-disc ratio was a stronger predictor for failure of LPI than extent of PAS. The poorer outcomes following LPI in cases with more advanced disease (PACG) compared with better achievement of IOP control in PAC cases without glaucomatous optic neuropathy are probably due to compromised trabecular meshwork function secondary to both synechial closure and non-synechial damage in areas of the angle unaffected by PAS.<sup>22</sup>

### *Angle configuration*

LPI acts by eliminating pupil block and altering the configuration of the angle to relieve appositional closure. This outcome can be quantified using gonioscopy or angle imaging techniques. Gonioscopic assessment of angle width can be performed following LPI. A study of Chinese primary angle closure suspects (PACS) undergoing LPI found, that in 19% cases there was UBM confirmation of residual appositional angle closure following laser.<sup>23</sup> In contrast gonioscopic comparison of pre- and post-LPI angle width in Mongolian subjects demonstrated that in the majority of cases appositional angle closure was relieved after

laser with a mean increase of two Shaffer grades.<sup>18</sup> These findings support the theory that non-pupil block mechanisms may play more of a role in the pathogenesis of angle closure in some Asian populations. A correlation between failure of LPI to relieve appositional angle closure and future clinical measures of poorly controlled disease including IOP and progression of glaucomatous optic neuropathy has yet to be demonstrated by a prospective study.

The effect of LPI on the extent of synechial angle closure is another important outcome. Documentation of the extent of PAS angle involvement is unreliable and subject to inter and intra-observer variability. This makes it difficult to demonstrate the effect of LPI on PAS development. In cases in which there is residual appositional closure following LPI there may be progressive synechial closure of the angle, but data supporting this are limited.

## **Argon laser peripheral iridoplasty (iridoplasty)**

### *Overview*

Iridoplasty is a method of opening an appositionally closed angle in situations in which laser iridotomy either cannot be performed, or does not eliminate appositional angle closure because mechanisms other than pupillary block are present. The procedure consists of placing contraction burns (long duration, low power, and large spot size) in the extreme iris periphery to contract the iris stroma between the site of the burn and the angle, physically pulling open the angle. Iridoplasty is useful in managing an attack of acute angle closure (AAC), either as a primary measure or when medications fail to control intraocular pressure.

## **Indications for iridoplasty**

### *Acute angle closure*

Iridoplasty is effective in controlling acute angle closure that is unresponsive to medical therapy and in which corneal edema, a shallow anterior chamber, or marked inflammation precludes immediate laser iridotomy, opening the angle in those areas in which there are no PAS.<sup>24-28</sup> In a prospective study of ten eyes with medically unbreakable attacks lasting two to five days, mean pre-laser IOP was 54.9 mmHg and two to four hours post-laser was 18.9 mmHg.<sup>26</sup> Even when extensive PAS are present, the IOP may be normalized. The effect lasts sufficiently long for the cornea and anterior chamber to clear so that iridotomy can be performed.

Iridoplasty may also be used as primary therapy in eyes with AAC, either with or without preliminary treatment with topical medications.<sup>24-34</sup> Immediate iridoplasty for acute attacks after initial treatment with 4% pilocarpine and 0.5% timolol was successful when treatment comprised either 180°<sup>31</sup> or 360°.<sup>30</sup>

A randomized trial comparing iridoplasty and medications was performed in consecutive patients presenting with AAC and IOP over 40 mmHg, who were not amenable to immediate laser peripheral iridotomy.<sup>34</sup> All patients received topical 4% pilocarpine and 0.5% timolol and were then randomized to immediate iridoplasty or both intravenous and oral acetazolamide until IOP normalized. The mean IOP in the lasered group was reduced from  $60.8 \pm 11.6$  mmHg at presentation to  $20.6 \pm 10.1$  mmHg at one hour after iridoplasty. The duration of attack did not affect the efficacy of iridoplasty. Longer follow up (mean 15.7 months) of these patients revealed no significant differences between the two groups in mean IOP, requirement for antiglaucoma medications, or the extent of PAS.<sup>35</sup>

Primary iridoplasty is also effective in attacks of acute phacomorphic angle closure.<sup>24,36,37</sup> In a recent study, ten consecutive patients with acute phacomorphic angle closure were treated with topical 1% atropine, 0.5% timolol, and immediate iridoplasty.<sup>36</sup> After iridoplasty, the mean IOP was reduced from  $56.1 \pm 12.5$  mmHg to  $37.6 \pm 7.5$  mmHg at 30 minutes,  $25.5 \pm 8.7$  mmHg at 120 minutes, and  $13.6 \pm 4.2$  mmHg at one day. All ten patients had uncomplicated cataract extraction soon after iridoplasty. No complications from the laser procedure were encountered. In acute phacomorphic angle closure, the eye is often severely inflamed, as these patients have usually been referred after being treated unsuccessfully for a few days. Breaking the attack with iridoplasty may allow a week or more for the inflammation and folds in Descemet's to clear, permitting cataract extraction under conditions much closer to ideal. Any element of pupillary block is treated with iridotomy as soon as possible (usually within two to three days) after breaking the attack.

#### *To eliminate appositional closure in the presence of a patent iridotomy*

If pupillary block is either not a component mechanism of the angle closure or has been eliminated by iridotomy, physical blockage of the angle may be eliminated by iridoplasty.

#### *Plateau iris syndrome*

Iridoplasty increases angle width in eyes with plateau iris configuration. Of 23 eyes with a mean follow-up of 79 months, the angle in 20 eyes (87.0%) remained open throughout follow-up after only one treatment.<sup>38</sup> In three eyes, there was gradual re-closure of the angle years later, but these were re-opened and maintained open by a single repeat treatment. No filtration surgery was necessary in these patients during follow-up.

A combined laser technique, with iridoplasty and sequential laser peripheral iridotomy in one sitting, has been proposed as a primary treatment for eyes with plateau iris syndrome.<sup>39</sup> Iridoplasty is also effective at opening appositionally closed segments of the angle in pseudo-plateau iris syndrome resulting from iridociliary cysts.<sup>40</sup>

*Angle closure related to size or position of the lens*

Angle closure caused by an enlarged lens or pressure posterior to the lens is not often responsive to iridotomy, although a component of pupillary block may be present and should be eliminated by iridotomy. These include such types of angle closure as ciliary block, lens intumescence, anterior subluxation of the lens, or anterior lens displacement secondary to ciliary body edema from panretinal photocoagulation, scleral buckling procedures, or acquired immunodeficiency syndrome. In these situations in which the angle remains appositionally closed after laser iridotomy, the apposition can often be partially or entirely eliminated by iridoplasty.<sup>41-44</sup>

**Contra-indications to iridoplasty***Corneal edema or opacification*

Moderate degrees of corneal edema are not a contraindication to iridoplasty in eyes with AAC. If necessary, glycerin may help clear the cornea temporarily to facilitate performing the procedure. Treatment of only 180° of the peripheral iris may be sufficient to abort the attack, and so obstruction to optical access to part of the peripheral iris, *e.g.*, by pterygium, need not be a contraindication.<sup>32</sup>

*Flat anterior chamber*

If the iris is apposed to the cornea, any attempt at photocoagulation will result in damage to the corneal endothelium. If the anterior chamber is very shallow, laser applications should be timed enough apart so that heat generated can dissipate. The first burn will contract the iris stroma and pull adjacent areas of the angle open, so that succeeding burns will create less or no visible endothelial damage. The effect of iridoplasty on corneal endothelial cell counts has not been reported.

*Synechial angle closure*

Iridoplasty is successful in relieving appositional closure, but not that due to PAS in eyes with uveitis, neovascular glaucoma, or the iridocorneal-endothelial (ICE) syndrome. Although iridoplasty has been reported to break PAS,<sup>45</sup> others have been unable to reproduce this.

Eyes with chronic angle closure and a combination of PAS and appositional closure can respond to iridoplasty with opening of the appositionally closed portions of the angle. Of 11 eyes with IOP > 20 mmHg despite maximal medical therapy, all responded with initial lowering of IOP initially and seven remained controlled at six months, while four required trabeculectomy.<sup>46</sup>

## Iridoplasty techniques

### *Pretreatment measures*

The patient is treated with one drop of 4% pilocarpine to constrict the pupil. Brimonidine can be administered as prophylaxis against IOP spikes. It should be noted that brimonidine has never specifically been studied in a randomized, prospective, masked study to determine whether it is effective as in other laser procedures, but has been taken empirically to do so.

### *Laser parameters*

The argon laser is set to produce contraction burns (500  $\mu\text{m}$  spot size, 0.5 to 0.7 second duration, and, initially, 80-100 mW power). With the Abraham lens in place, the beam is aimed at the most peripheral portion of the iris possible. One of the most common errors resulting in failure of the procedure is spot placement in the mid-periphery of the iris rather than the extreme periphery. It is useful to allow a thin crescent of the aiming beam to overlap the sclera at the limbus. The patient should look slightly, but not too far, in the direction of the iris being treated in order to achieve more peripheral spot placement.

The foot pedal should be pressed for the entire duration of the burn, unless bubble formation and pigment release occur. The contraction effect is immediate and usually accompanied by noticeable deepening of the peripheral anterior chamber at the site of the burn. The patient should be warned that he or she will feel the burns and that a small amount of discomfort is necessary to produce adequate iris contraction. A lack of visible contraction and deepening of the peripheral anterior chamber at any site is suggestive of too low a power or PAS. The power should be increased initially to see if contraction is improved, particularly if the patient does not feel the burn. If bubble formation occurs or if pigment is released into the anterior chamber, the power should be reduced. Histopathologic examination suggests that the short-term effect is related to heat shrinkage of collagen and the long-term effect to be secondary to contraction of a fibroblastic membrane in the region of the laser application.<sup>47</sup>

Lighter irides generally require more power than darker ones. The surgeon should adjust the power as necessary to obtain visible stromal contraction. Occasionally, in light gray irides, a 200  $\mu\text{m}$  spot size may be more effective in achieving significant stromal contraction. The use of a smaller spot size requires a much larger number of burns to achieve the same result and, particularly with high power settings, may result in stromal destruction and pigment release.

Treatment consists of placing approximately 20 to 24 spots over 360°, leaving approximately two spot-diameters between each spot and avoiding large visible radial vessels if possible. Although rare, iris necrosis may occur if too many spots are placed too closely together. If this treatment is insufficient, more spots may be given at a later sitting.

The presence of an arcus senilis should be ignored. An extremely shallow anterior chamber and corneal edema, which are relative contraindications to laser iridotomy, do not preclude peripheral iridoplasty.

Other laser settings published for this type of burn, most commonly 200  $\mu\text{m}$ , 0.1 or 0.2 second duration and 200 mW power, often provide insufficient contraction and result in bubble formation or pigment liberation into the anterior chamber. When used through the angled mirror of a gonioscopy lens, they are more likely to result in stromal destruction or inadvertent damage to the trabecular meshwork. The laser beam strikes the iris tangentially and results in a more diffuse burn with less peripheral stromal contraction and thinning.

Two additional situations should be noted. First, when iridoplasty needs to be repeated because of recurrence of appositional closure at some point after the angle has been initially opened, it is possible to place the contraction burns further peripherally than had been initially possible. The reason for this is evident if one conceptualizes the geometry of the peripheral iris. When the angle is closed, burns placed just inside the point of apposition pull open the angle and expose iris stroma further peripherally. This area can be treated on a subsequent occasion, if necessary.

Secondly, a few angles have a very sharply defined plateau which on indentation forms almost a right angle and takes firm pressure to indent open. This type of plateau iris often does not respond well to contraction burns placed with the Abraham lens but require burns placed through one of the angled mirrors with magnification buttons directly into the peripheral angle. A 200  $\mu\text{m}$  spot size should be used in this circumstance.

### *Postoperative treatment*

Immediately after the procedure, the patient can be given a drop of topical steroid. Although it is not proven, some surgeons use topical apraclonidine or brimonidine to prevent an acute rise in IOP. Gonioscopy should be performed to assess the effect of the procedure immediately if pilocarpine has not been used. If it has, it is better to evaluate the success of the procedure at a subsequent visit. Patients may be treated with topical steroids four to six times daily for seven days. Intraocular pressure is monitored postoperatively as after any other anterior segment laser procedure and patients treated as necessary if a postlaser IOP rise occurs.

### **Complications of iridoplasty**

A mild postoperative iritis is common and responds to topical steroid treatment, seldom lasting more than a few days. The patient may experience transient ocular irritation.

Because iridoplasty is often performed on patients with extremely shallow peripheral anterior chambers, diffuse corneal endothelial burns may occur. As opposed to the dense white, sharply delineated burns seen during laser iridotomy, endothelial burns seen during peripheral iridoplasty are larger and much less opaque. If endothelial burns present a problem early in the procedure, they may be minimized by placing an initial contraction burn more centrally before placing the peripheral burn. This first burn will deepen the anterior chamber peripheral to it, allowing the more peripheral burn to be placed with less adverse consequences. In virtually all cases, the endothelial burns disappear within several days and have not proved to be a major complication. The effect of this complication on endothelial cell density and function is unknown.

Hemorrhage does not occur, because of the lower power density used to produce contraction burns as opposed to destructive ones. A transient rise in intraocular pressure can occur as with other anterior segment laser procedures. Lenticular opacification has not occurred with peripheral iridoplasty, and theoretically this problem would be highly unlikely.

Pigmented burn marks may develop at the sites of laser applications in some eyes treated with iridoplasty. These are generally of no serious consequences.<sup>48</sup> Iris atrophy may rarely develop and this can be avoided by using the lowest laser power to achieve iris contraction, and also by leaving untreated spaces between two laser application sites, and not allowing the laser marks to become confluent. When IOP is rapidly reduced in acute primary angle closure by iridoplasty, decompression retinopathy can rarely occur.<sup>35</sup>

A few patients have developed relatively widely dilated pupils after laser, enough to cause photophobia and/or anxiety over the appearance.

### **Need for re-treatment after iridoplasty**

Although iridoplasty may provide long-term benefits in eyes with plateau iris, patients need to be followed closely to detect recurrence of appositional closure. Patients should be examined gonioscopically at regular intervals and further treatment given if necessary.

### **Conclusions for iridoplasty**

Iridoplasty is an outpatient laser procedure that may open up appositionally closed portions of the drainage angle. Since it does not eliminate pupillary block, laser peripheral iridotomy is still indicated if pupillary block is present.

Iridoplasty has taken on new indications in recent years. It is now a viable alternative first-line treatment for AAC, in place of systemic IOP-lowering medications. Further studies are needed to assess whether iridoplasty may also reduce the rate of conversion to CAC after AAC. Iridoplasty may also have a



role in the treatment of acute phacomorphic angle closure in the future. Techniques of iridoplasty have also been refined over the years. Nowadays, lower power, longer duration, and larger spot sizes (contraction burns) are preferred over those laser settings proposed by the original proponents of the procedure.

### Consensus Statements

- Laser iridotomy should be performed in all eyes with an acute episode of angle closure, the contralateral fellow of all such eyes, and in eyes with established angle closure causing raised intraocular pressure and/or peripheral anterior synechiae. Eyes with anatomically narrow angles and typical symptoms of angle closure should also be treated. Consideration can be given to laser iridotomy in eyes with iridotrabecular apposition.
- Iridoplasty can be considered in eyes with residual appositional closure provided a patent iridotomy is present.
- Medical treatment should not be used as a substitute for laser iridotomy or surgical iridectomy in patients with PAC or PACG.
- Iridoplasty is as effective as pressure lowering medication in controlling intraocular pressure in people with an acute attack of angle closure.
- Iridoplasty is successful in relieving appositional closure due to plateau iris configuration in asymptomatic cases.

*Comment:* Additional data in larger numbers of patients are needed.

*Comment:* Iridoplasty may also have a role in managing cases of phacomorphic and pseudo-plateau iris configuration caused by iris cysts.

### Medical treatment for PACG

The management of symptomatic ('acute') angle closure is covered in an accompanying section dedicated to this particular topic.

### Indications for treatment

Patients presenting with elevated IOP due to asymptomatic PAC or PACG may need treatment with glaucoma medications prior to laser iridotomy. Once iridotomy, and when indicated, iridoplasty have been done to relieve appositional closure any residual elevation of IOP may be controlled by the use of glaucoma medications. All the major classes of topical glaucoma medication can be used in angle closure patients in the same way as they are used for management of POAG. Topical beta-blockers, carbonic anhydrase inhibitors and alpha-2-agonists can be used when there are no contraindications.<sup>49</sup> Regular measurement of IOP together with visual field analysis and optic nerve head assessment should be used to monitor the effectiveness of treatment.



## Specific medications for the treatment of PACG

### *Prostaglandin analogues*

In a randomized controlled trial comparing latanoprost and timolol 0.5% in Asian patients with PACG, a 34.2% reduction of IOP was measured in the latanoprost treated group, and a 22.6% IOP reduction in the timolol group.<sup>50</sup> This study reported no correlation between efficacy of latanoprost and extent of synechial closure of the angle.<sup>51</sup> Two prospective studies conducted in Indian patients with PACG also confirmed that latanoprost and bimatoprost treatment result in significant lowering of IOP.<sup>52,53</sup> A recent case series conducted in Korean patients found that even in eyes with 360 degrees of PAS, latanoprost treatment is effective in lowering IOP.<sup>54</sup>

### *Pilocarpine*

Pilocarpine is the most commonly used miotic agent. In the past it was frequently used in the management of angle closure as it acts to constrict the pupil and pull the iris away from the trabecular meshwork. But long-term use of pilocarpine can result in the development of posterior synechiae and pupil miosis making cataract surgery technically difficult. Miotic agents have not been shown to prevent progression of angle closure and should never be used in lieu of an iridotomy.

UBM and Scheimpflug studies have shown that pilocarpine increases angle width in patients with narrow angles<sup>55</sup> but paradoxically its use in normal eyes may result in shallowing of the anterior chamber.<sup>56</sup> This effect may be exacerbated in eyes with pseudoexfoliation, phacomorphic glaucoma and aqueous misdirection. For these reasons, pilocarpine is contraindicated in cases with lens induced and retro-lenticular mechanisms causing angle closure. Despite its complications and side-effects, pilocarpine can be very effective in controlling IOP. It is inexpensive and widely available. It can be used in a low dose form for angle closure patients with plateau iris syndrome and residual appositional closure following iridotomy and iridoplasty.<sup>57</sup>

### *Other topical medications in management of angle closure*

There are no robust data to guide the specific use of other agents in control of IOP in angle closure. The use of other agents must be decided based on the specific features of each case.

## Summary and recommendations for medical treatment of PACG

Medical treatment of PAC and PACG can be instituted to achieve short term pressure control. Long-term medical management can be used, once the patient

has been treated with iridotomy, and iridoplasty if indicated. Treatment with any of the classes of glaucoma medications is appropriate depending on their effectiveness, tolerability and availability to individual patients. Pilocarpine should be reserved for those cases in which there is residual appositional closure following laser treatment and for patients who are unresponsive to other glaucoma medications and wish to avoid surgical intervention. Pilocarpine is contra-indicated in patients with lens induced or retro-lenticular mechanisms.

### Consensus Statements

- Medical treatment should not be used as a substitute for laser iridotomy or surgical iridectomy in patients with PAC or PACG.
- Prostaglandin analogues appear to be the most effective medical agent in lowering IOP following laser iridotomy, regardless of the extent of synechial closure.

### Target IOP in PACG

Patients with PACG often present with higher IOP and more advanced visual field loss than those with POAG.<sup>58</sup> These findings have led some to postulate that PACG may be a more IOP-dependent disease. The nature of elevated IOP may also differ in PACG with greater swings and diurnal variation of IOP.<sup>59</sup> While there is now evidence available to guide us in setting target IOPs when treating POAG, there are no published studies investigating what IOP levels are required to prevent progression of glaucomatous optic neuropathy in PACG.

### References

1. Del-Priore LV, Robin AL, Pollack IP. Neodymium:YAG and argon laser iridotomy. Long-term follow-up in a prospective, randomized controlled trial. *Ophthalmology* 1988;95:1207-1211.
2. Robin A, Pollack IP. A comparison of neodymium-YAG and argon laser iridotomies. *Ophthalmology* 1984;91:1011-1016.
3. Fleck BW, Wright E, Fairley EA. A randomized prospective comparison of operative peripheral iridectomy and Nd:YAG laser iridotomy treatment of acute angle closure glaucoma: 3 year visual acuity and intraocular pressure control outcome. *Br J Ophthalmol* 1997;81:884-888.
4. Jin JC, Anderson DR. The effect of iridotomy on iris contour. *Am J Ophthalmol* 1990;110:260-263.
5. Lowe RF. Acute angle-closure glaucoma. The second eye: an analysis of 200 cases. *Br J Ophthalmol* 1962;46:641-650.
6. Snow JT. Value of prophylactic iridectomy on the second eye in angle-closure glaucoma. *Trans Ophthalmol Soc UK* 1997;97:189-191.

7. Spaeth GL, Idowu O, Seligsohn A, et al. The effects of iridotomy size and position on symptoms following laser peripheral iridotomy. *J Glaucoma* 2005;14:364-367.
8. Fleck BW. How large must an iridotomy be? *Br J Ophthalmol* 1990;74:583-588.
9. Quigley HA. Long-term follow up of laser iridotomy. *Ophthalmology* 1981;88:218-224.
10. Lim L, Seah SKL, Lim ASL. Comparison of argon laser iridotomy and sequential argon and YAG laser iridotomy in dark irides. *Ophthal Surg Lasers* 1996;27:285-288.
11. Ho T, Fan R. Sequential argon-YAG laser iridotomies in dark irides. *Br J Ophthalmol* 1992;76:329-331.
12. Robin AL. The role of Apraclonidine hydrochloride in laser therapy for glaucoma. *Trans Am Ophthalmol Soc* 1989;87:729-761.
13. Pollack IP. Use of Argon laser energy to produce iridotomies. *Ophthalmic Surg* 1980;11:506-515.
14. Kozobolis VP, Detorakis ET, Vlachonikolis IG, Pallikaris IG. Endothelial corneal damage after neodymium:YAG laser treatment: Pupillary membranectomies, iridotomies, capsulotomies. *Ophthal Surg Lasers* 1998;29:793-802.
15. Lewis R, Perkins TW, Gangnon R, et al. The rarity of clinically significant rise in intraocular pressure after laser peripheral iridotomy with apraclonidine. *Ophthalmology* 1998;105:2256-2259.
16. Lim LS, Husain R, Gazzard G, et al. Cataract progression after prophylactic laser peripheral iridotomy: potential implications for the prevention of glaucoma blindness. *Ophthalmology* 2005;112:1355-1359.
17. Salmon JF. Long-term intraocular pressure control after Nd: YAG laser iridotomy in chronic angle-closure glaucoma. *J Glaucoma* 1993;2:291-296.
18. Nolan WP, Foster PJ, Devereux JG, et al. YAG laser iridotomy treatment for primary angle-closure in East Asian eyes. *Br J Ophthalmol* 2000;84:1255-1259.
19. Rosman M, Aung T, Ang L, et al. Chronic angle-closure with glaucomatous damage: long-term clinical course in a North American population and comparison with an Asian population. *Ophthalmology* 2002;109:2227-2231.
20. Kim YY, Jung HR. Dilated miotic-resistant pupil and laser iridotomy in primary angle-closure glaucoma. *Ophthalmologica* 1997;211:205-208.
21. Yamamoto T, Shirato S, Kitazawa Y. Treatment of primary angle-closure glaucoma by argon laser iridotomy: a long-term follow up. *Jpn J Ophthalmol* 1985;29:1-12.
22. Sihota R, Lakshmaiah NC, Walia KB, et al. The trabecular meshwork in acute and chronic angle closure glaucoma. *Indian J Ophthalmol* 2001;49:255-259.
23. He M, Foster PJ, Johnson GJ, Khaw PT. Angle-closure glaucoma in East Asian and European people. Different diseases? *Eye* 2006;20:3-12.
24. Ritch R. Argon laser treatment for medically unresponsive attacks of angle-closure glaucoma. *Am J Ophthalmol* 1982;94:197.
25. Matai A, Consul S. Argon laser iridoplasty. *Indian J Ophthalmol* 1987;35:290-292.
26. Chew P, Chee C, et al. Laser treatment of severe acute angle-closure glaucoma in dark Asian irides: The role of iridoplasty. *Lasers and Light in Ophthalmology* 1991;4: 41-42.
27. Lim AS, Tan A, et al. Laser iridoplasty in the treatment of severe acute angle closure glaucoma. *Int Ophthalmol* 1993;17:33-36.
28. Malis V. Iridoplasty and primary angle-closure glaucoma. *Ceska a Slovenska Oftalmologie* 2001;57:22-26.
29. Agarwal HC, Kumar R, et al. Argon laser iridoplasty: A primary mode of therapy in primary angle-closure glaucoma. *Indian J Ophthalmol* 1991;39:87-90.
30. Lam DSC, Lai JSM, et al. Immediate argon laser peripheral iridoplasty as treatment for acute attack of primary angle-closure glaucoma. A preliminary study. *Ophthalmology* 1998; 105:2231-2236.
31. Lai JSM, Tham CCY, et al. Limited argon laser peripheral iridoplasty as immediate treatment for an acute attack of angle-closure glaucoma: A preliminary study. *Eye* 1999;13:26-30.

32. Tham CCY, Lai JSM, et al. Immediate ALPI for acute attack of angle-closure glaucoma (addendum to previous report)(letter). *Ophthalmology* 1999;106:1042-1043.
33. Lai JSM, Tham CCY, et al. Laser peripheral iridoplasty as initial treatment of acute attack of primary angle-closure: A long-term follow-up study. *J Glaucoma* 2002;11:484-487.
34. Lam DSC, Lai JSM, et al. Argon laser peripheral iridoplasty versus conventional systemic medical therapy as the first line treatment of acute angle closure: a prospective randomized controlled trial. *Ophthalmology* 2002;109:1591-1596.
35. Lai JSM, Tham CCY, et al. To compare argon laser peripheral iridoplasty (ALPI) against systemic medications in treatment of acute primary angle-closure: mid-term results. *Eye* 2006;20:309-314.
36. Tham CCY, Lai JSM, et al. Immediate argon laser peripheral iridoplasty (ALPI) as initial treatment for acute phacomorphic angle-closure (phacomorphic glaucoma) before cataract extraction: a preliminary study. *Eye* 2005;19:778-783.
37. Yip PPW, Leung WY, et al. Argon laser peripheral iridoplasty in the management of phacomorphic glaucoma. *Ophthalmic Surg Lasers Imaging* 2005;36:286-291.
38. Ritch R, Tham CCY, et al. Argon laser peripheral iridoplasty in the management of plateau iris syndrome: long-term follow-up. *Ophthalmology* 2004;111:104-108.
39. Peng D, Zhang X, Yu K. Argon laser peripheral iridoplasty and laser iridectomy for plateau iris glaucoma. *Zhonghua Yan Ke Za Zhi* 1997;33:165-168.
40. Crowston JG, Medeiros FA, et al. Argon laser iridoplasty in the treatment of plateau-like iris configuration as result of numerous ciliary body cysts. *Am J Ophthalmol* 2005;139:381-383.
41. York K, Ritch R, et al. Argon laser peripheral iridoplasty: Indications, techniques and results. *Invest Ophthalmol Vis Sci* 1984;25(Suppl):94.
42. Burton TC, Folk JC. Laser iris retraction for angle-closure glaucoma after retinal detachment surgery. *Ophthalmology* 1988;95:742-748.
43. Ritch R, Solomon IS. Glaucoma surgery. In: L'Esperance FA (ed). *Ophthalmic lasers*. St. Louis, CV Mosby, 1989.
44. Koster HR, Liebmann JM, et al. Acute angle-closure glaucoma in a patient with acquired immunodeficiency syndrome successfully treated with argon laser peripheral iridoplasty. *Ophthalmic Surg* 1990;21:501-502.
45. Wand M. Argon laser goniotomy for synechial angle closure. *Arch Ophthalmol* 1992;110:353-367.
46. Chew PTK, Yeo LMW. Argon laser iridoplasty in chronic angle-closure glaucoma. *Int Ophthalmol* 1995;19:67-70.
47. Sassani JW, Ritch R, et al. Histopathology of argon laser peripheral iridoplasty. *Ophthalmic Surg* 1993;24:740-745.
48. Lai JSM, Tham CCY, et al. Laser peripheral iridoplasty as initial treatment of acute attack of primary angle-closure: A long-term follow-up study. *J Glaucoma* 2002;11:484-487.
49. Sakai H, Shinjo S, Nakamura Y, et al. Comparison of latanoprost monotherapy and combined therapy of 0.5% Timolol and 1% dorzolamide in chronic primary angle-closure glaucoma (CACG) in Japanese patients. *J Ocul Pharmacol Ther* 2005;21:483-489.
50. Chew PT, Aung T, Aquino MV, Rojanapongpun P, EXACT Study group. Intraocular pressure-reducing effects and safety of latanoprost versus timolol in patients with chronic angle-closure glaucoma. *Ophthalmology* 2004;111:427-434.
51. Aung T, Chan YH, Chew PT, EXACT Study group. Degree of angle closure and intraocular pressure-lowering effect of latanoprost in subjects with chronic angle-closure glaucoma. *Ophthalmology* 2005;112:267-271.
52. Sihota R, Saxena R, Agarwal HC, Gulati V. Cross-over comparison of timolol and latanoprost in chronic primary angle-closure glaucoma. *Arch Ophthalmol* 2004;122:185-189.
53. Agarwal HC, Gupta V, Sihota R. Effect of changing from concomitant timolol pilocarpine to bimatoprost monotherapy on ocular blood flow and IOP in primary chronic angle-closure glaucoma. *J Ocul Pharmacol Ther* 2003;19:105-112.

54. Kook MS, Cho HS, Yang SJ, et al. Efficacy of latanoprost in patients with chronic angle-closure glaucoma and no visible ciliary-body face: a preliminary study. *J Ocul Pharmacol Ther* 2005;21:75-84.
55. Kobayashi H, Kobayashi K, Kiryu J, Kondo T. Pilocarpine induces an increase in the anterior chamber angular width in eyes with narrow angles. *Br J Ophthalmol* 1999;83:553-558.
56. Hung L, Yang CH, Chen MS. Effect of pilocarpine on anterior chamber angles. *J Ocul Pharmacol Ther* 1995;11:221-226.
57. Ritch R, Lowe RF, Reyes A. Therapeutic overview of angle closure glaucoma. In: Ritch R, Shields MB, Krupin T (eds). *The Glaucomas*. St Louis, CV Mosby, 1989.
58. Gazzard G, Foster PJ, Devereux JG, et al. Intraocular pressure and visual field loss in primary angle-closure and primary open angle glaucomas. *Br J Ophthalmol* 2003;87:720-725.
59. Shapiro A, Zamberman H. Changes of intraocular pressure of patients with angle-closure glaucoma. *Br J Ophthalmol* 1979;63:225-227.

# DETECTION OF PRIMARY ANGLE CLOSURE AND ANGLE CLOSURE GLAUCOMA

*Co-chairs:* David S. Friedman, Ravi Thomas,  
Poule Helge Alsbirk and Gus Gazzard



David S. Friedman

## Introduction

This section reviews the current state of the evidence in support of screening strategies for detecting asymptomatic primary angle closure glaucoma (PACG) and its precursor states (*e.g.*, iridotrabecular contact) as well as reviewing the evidence supporting treating persons identified in this process. Discussions of screening are often confusing owing to the various possible settings in which screening can occur. The term ‘screening’ is often loosely used to mean population-based screening and also for what is called opportunistic screening; the latter includes case detection, where we use the opportunity presented to examine (‘screen’) all patients who come to us. Such case detection or ‘screening’ in the clinic is altogether a different program from population based screening and the recommendations regarding each of these differ. While we will mention the current state of the art for population-based screening, most of the recommendations in this document pertain to clinic-based case detection. In order to evaluate the issue of screening for glaucoma, it is important to review some definitions that will be used in this document.

## Definitions

**Screening** = population-based detection of disease or pre-disease states.

**Case detection** (opportunistic screening) = the active detection of disease or pre-disease states when patients visit clinics and hospitals.

**Prevalence** of a condition = the proportion of patients with the target disease or pre-disease state in the population tested.

**Sensitivity** = the ability of a test to correctly identify those true positives who have PACG or its precursor conditions (PAC or PACS – suspect PAC)

**Specificity** = the ability of a test to correctly identify those true negatives or normals who do not have PACG or its precursor states.

*Angle Closure and Angle Closure Glaucoma, pp. 55-63*

*edited by Robert N. Weinreb*

© 2006 Kugler Publications, The Hague, The Netherlands

**Positive Predictive Value (PPV)** of a test = the proportion of patients with positive results who in truth have the condition for which one is screening.

**Negative Predictive Value (NPV)** of a test = the proportion of patients with negative test results who in truth do *not* have the condition.

The PPV and NPV of a test are dependant on the prevalence of disease in the population being tested. As shown in Figure 1, assuming a test with 85% sensitivity and 85% specificity, the positive predictive value (PPV) will increase with increasing prevalence, while the negative predictive value will decrease.

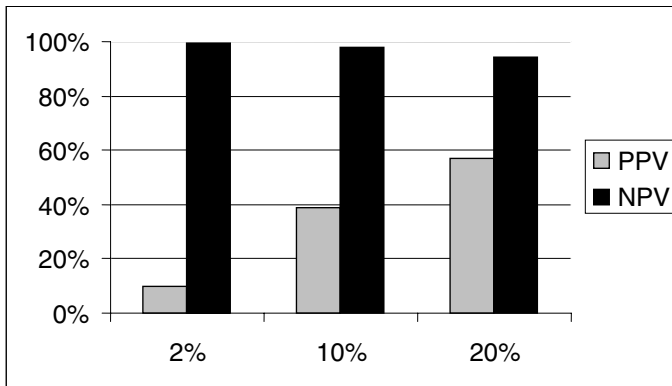


Fig. 1.

As this figure shows, in order to increase the PPV of a test a higher prevalence of disease is desirable. We can ‘increase’ the presumed prevalence of PACG and precursor states by targeting high-risk groups such as the elderly, persons with family history of glaucoma, and so on.

### Population-based screening

Deciding to screen for disease is a process that requires careful consideration of both the benefits of early disease detection and the harms of excessive treatment and false reassurance. The World Health Organization recommends that the criteria listed here be fulfilled before any population based screening is undertaken.<sup>1</sup>

- The disease must be an important public health problem.
- There must be a recognizable latent or early stage, during which persons with the disease can be identified before symptoms develop.
- There must be an appropriate, acceptable and reasonably accurate screening test.

- There must be an accepted and effective treatment for patients with the disease that must be more effective at preventing morbidity when initiated in the early asymptomatic stage than when begun in the later, symptomatic stages of the disease.
- The cost of case finding must be economically balanced in relation to possible expenditure on medical care as a whole.

Other questions that need to be asked before embarking on any screening program include:

- Does early diagnosis lead to improved clinical outcomes in terms of visual function and quality of life?
- Can the health system cope with the additional clinical time and resources required to confirm the diagnosis and provide long term care for those who screen positive for a chronic disease such as glaucoma?
- Will the patients in whom early diagnosis is achieved comply with subsequent recommendations and treatment regimens?
- Are the cost, accuracy, and acceptability of the screening tests adequate for our purpose?

### **Detection of PAC and PACG**

Recent estimates are that about one fourth of the glaucoma in the world will be caused by angle closure in the year 2010.<sup>2</sup> Tonometry will only detect angle closure patients with elevated IOP. The structural and functional tests described for POAG (optic disc examination, perimetry) will only detect angle closure that has damaged the disc or visual field. Since the end-stage findings of PACG are similar to those of POAG, screening strategies that detect functional damage in POAG may also be suitable for manifest PACG. However, such tests will not detect eyes without functional damage, and thus not eyes at risk for developing angle closure glaucoma in their pre-disease state.

At present, the gold standard for the identification of angle closure and eyes at risk is to examine the angle using a gonioscope. The clinical expertise and instrumentation required render gonioscopy inappropriate for screening, although it is an important tool for case detection.

Other methods to identify eyes at risk of angle closure include the measurement of anterior chamber depth (ACD) as well as determination of the anterior chamber depth / axial length ratio.<sup>3-7</sup> Such tests may be useful in population-based screening settings in order to detect persons at high risk so that one can avoid having to perform gonioscopy on all persons. ACD in the shallow range has long been known as an important anatomical risk factor. Ultrasound and – more precisely – optical pachymetry methods are useful, but the equipment can be costly and requires some experience. Newer methods are currently being developed (*see* Appendix C).



### *Flashlight test*

Other easier techniques include the flashlight test (potentially useful when no slitlamp biomicroscope is available),<sup>8</sup> and the Van Herick test (limbal ACD, LACD). In the flashlight test a light is shone from the temporal side onto the cornea, parallel but anterior to the iris. A shadow on the nasal limbus identifies an eye with a shallow chamber as being at risk for angle closure. In one report the sensitivity of the flashlight test was reported to be 80-86% with a specificity of 69-70%.<sup>8</sup> The sensitivity and specificity are too low for either population-based screening, or clinic-based case detection. However, it may be useful in combination with LACD to increase the negative predictive value.<sup>9</sup>

### *Limbal Anterior Chamber Depth (LACD)*

LACD measurement is performed using a slit beam to compare the peripheral anterior chamber depth to the thickness of the cornea. One study comparing this test to gonioscopic angle closure (defined as 270° of angle in which the pigmented trabecular meshwork (TM) is not visible in primary gaze allowing minor tilting of the lens) reported the sensitivity and specificity of the test to be 61.9 % and 89.3 %, respectively.<sup>9</sup> Expressing the test in slightly more refined increments gives similar results. The grade  $\leq 15\%$  CT gave sensitivity and specificity at 84 and 86% for detection of narrow angles (less than 90° of posterior trabecular meshwork visible in primary position). At  $\leq 25\%$  specificity was only 65%, – i.e., 1/3 false positives, but sensitivity increased to 99%. Thus LACD estimation is a very useful fast primary procedure at the slitlamp for all elderly patients that can be used to detect high risk patients. For patients with glaucoma, LACD estimation cannot replace gonioscopy.

Requiring two independent tests to both be positive increases specificity and decreases sensitivity. This may be desirable in population-based screening. For example, if the LACD test is positive AND the IOP is raised, the specificity for PACG improves to 99.3%. If the pupillary ruff is also abnormal, the probability may increase further.<sup>10</sup> Therefore, as far as a population based screening strategy is concerned, if the IOP is raised and the Van Herick test is positive, the specificity is high enough to actually treat the patient as having angle closure.

### **Anterior Chamber Depth (ACD)**

ACD is not considered a screening technique for office-based detection of angle closure. Gonioscopy is essential for accurate diagnosis and targeting appropriate therapy. In contrast, in population-based research studies looking at central ACD as a population-based screening tool have frequently not required gonioscopy of all subjects for their diagnostic criterion. The most detailed analysis of

screening using ACD comes from work in Mongolia.<sup>11</sup> The investigators compared optical pachymetry, slitlamp-mounted A-scan ultrasound and a handheld ultrasound probe. Optical methods performed best at detection of 'occludable' angles (90° TM or less seen on gonioscopy, which was performed in all persons). At a screening cutoff of 2.22 mm this gave a sensitivity of 85% and specificity of 84% in the Mongolian population aged 40 years or over. Congdon *et al.* found a sensitivity of 77% and specificity of 84% for ACD (by handheld ultrasound) alone in Taiwan (cut-off 2.70 mm including corneal thickness).<sup>12</sup> This improved to 88% and 92% with inclusion of IOP and to 84% and 83% with consideration of refractive error. Thus, particularly in populations with higher PAC prevalence, ACD might usefully determine a need for gonioscopy as a first screen but cannot replace gonioscopy in either population-based screening or clinic-based case detection. Higher equipment costs than required for LACD also need to be considered.

### **PACG prophylaxis for persons with iridotrabecular contact (primary angle closure suspects)**

Once PAC or PACG is established, LPI may be insufficient to control intraocular pressure.<sup>13</sup> This has led some to advocate early LPI in individuals at 'high risk' of PACG. While LPI appears relatively safe, and can be performed using portable equipment,<sup>14</sup> one has to consider potential adverse consequences of the procedure. LPI disrupts the natural flow of aqueous in the eye and theoretically may predispose to more rapid development of cataract.<sup>15</sup> This altered aqueous flow and the laser energy used during iridotomy may have other ramifications including the hastening of corneal endothelial cell dysfunction.<sup>16</sup> Cases of corneal decompensation following LPI have been reported.<sup>17</sup>

The literature provides little evidence supporting the benefit of LPI for individuals with gonioscopically visible iridotrabecular contact. Little is known about the natural history of eyes with this condition. Wilensky and colleagues enrolled 129 mostly European-derived subjects with 'occludable' angles and central anterior chamber depth (measured by optical pachymetry) less than 2.0 mm in a prospective study<sup>18</sup> over a five-year period at five separate centers. Some of these subjects had PAS or elevated IOP (baseline IOP had to be below 28 mmHg) and would have classified as PAC. Eight patients (6.2%) developed AAC and 17 (13.2%) developed either appositional closure, peripheral anterior synechiae (PAS) in at least 0.5 clock hours of the superior quadrant, worsening of vision, or other eye conditions (median follow-up 2.7 years). Dark room prone provocative testing did not consistently predict who would develop PAC or an acute attack during follow-up. This study in European-derived individuals demonstrates that a combined screening strategy using ACD and gonioscopy had a relatively low positive predictive value for the development of AAC and/or primary angle closure (19.4%). Furthermore, no comparison group

was studied to assess the benefit of prophylactic LI to this population. The study also was limited by slow recruitment and multiple study sites with limited standardization of study procedures.

Alsbirk<sup>19</sup> re-examined a Greenland Eskimo population (N = 75), aged 40+ at the time of the follow-up examination, who had been selected ten years earlier by a Van Herick score of *either* 0 or 1 (limbal chamber depth LACD < 0.25 CT), *or* 2 (LACD = 0.25), if ACD (cornea included) was  $\leq 2.70$  mm. At follow-up after ten years 12 (16%) of the probands had developed (5) or were newly discovered to have signs of angle closure (7). None had developed obvious optic nerve damage over the ten-year period (yet visual field testing was not available). Thus, according to the newer ISGEO terminology, all 12 had what is now called primary angle closure (PAC). Eight were found with symptoms: two with earlier AAC-attacks (now filtered), six with intermittent PAC, (two without PAS, but positive provocative tests, four others had PAS). Four were detected without symptoms, but with PAS. One had elevated IOP (26/25 mm) that increased to 54 with mydriasis, three others were normotensive. Findings were analyzed according to baseline findings for gonioscopy, ACD and LACD. Of 20 individuals with angles found to be 'suspect occludable' (a Shaffer grade cumulative score  $\leq 8$  over 4 quadrants) at baseline, seven (35%) developed PAC, as opposed to four of 49 (8%) estimated as non-occludable. Thus, the study showed that angle closure development can be predicted to some degree based on anatomical risk factors at the slit lamp. It also demonstrates that even among Greenland Eskimos (who have high rates of PACG) the risk of PACG was low over a ten-year period.

These two articles sum up the English literature on how well a physician seeing iridotrabecular contact on gonioscopy predicts the later development of acute or chronic angle closure in untreated eyes. Only European-derived individuals being followed by multiple glaucoma specialists and Greenland Eskimos being examined by a single trained observer were studied. In addition to these two publications, It has been reported that 22% (CI;10-34%) of a South Indian population with PACS progress to PAC (appositional or synechial) over a period of five years.<sup>20</sup> As was seen with the Greenland Eskimos, there were no cases of PACG over this period, and no episodes of acute ACG. The sample size was small and compatible with a true rate of developing AAC as high as 6%.

### **Risk factors and screening**

Lowe, Alsbirk and others have studied the anatomical predisposition towards PACG extensively in Caucasians and Eskimos.<sup>21-26</sup> They identified a relatively anterior lens position and a proportionally thicker lens as predisposing factors for PACG. Both of these conditions are associated with a shallow anterior chamber depth, one of the strongest risk factors for PACG. Affected eyes often (but

not invariably) are hypermetropic with a short axial length. Small corneal diameter and radius of curvature were found to be less important risk factors. However, even though PACG is much more common in China, there is some indication that normal Chinese subjects have similar mean anterior chamber depths to Caucasians, indicating that other factors may contribute to higher rates among Chinese.<sup>27</sup> While these traits are clearly risk factors for having PACG, none of the extensive work in this field has determined which of these, if any, are associated with a poor outcome for individuals with narrow angles who do not undergo prophylactic iridotomy. Other important risk factors that are associated with PACG and AAC attacks are female sex, age, refraction and race.<sup>6,12,28,29</sup>

Some have used provocative tests and assumed that an increase in IOP is a sign of a predisposition to PACG.<sup>30-34</sup> These tests include pharmacologic dilation, dark room provocation, prone positioning, and combinations. While some of these do indeed cause IOP spikes in individuals with gonioscopically evident iridotrabecular contact, it is not clear that such individuals are truly at risk for PACG under normal circumstances or that those who test negative are safe. With the exception of two prospective studies<sup>18,34</sup> almost no studies address the predictive value of a positive test. Wishart found that a provocative test using pilocarpine was of almost no use in determining who would benefit from laser iridotomy.<sup>34</sup> Wilensky reported a weak association with a positive dark room prone provocative test and the development of angle closure in right eyes only.<sup>18</sup> Therefore, while several studies have documented that individuals with a history of PACG or AAC are more likely to have positive tests, the implications of a positive provocative test for individuals with narrow angles are far from clear. Recently, dark room provocative tests with UBM or anterior segment OCT have been proposed,<sup>35</sup> however, the clinical utility of these provocative tests remains unproven.

### Consensus Statements

- Angle closure case detection or opportunistic screening should be performed in all persons forty years of age and older undergoing an eye examination.
- Given the low specificity of the flashlight test, it is not recommended for use in population-based screening or in the clinic.
- A shallow anterior chamber is strongly associated with angle closure. The use of ACD for population-based screening is as yet unproven.
- Many clinicians currently perform iridotomy as prophylaxis in the presence of any visible iridotrabecular contact.

*Comment:* Published evidence is lacking to justify this practice since it is unknown whether LPI is effective at preventing AAC, PAC, and PACG from developing in individuals with gonioscopically detected iridotrabecular contact.

*Comment:* Research is needed to determine racial/ethnic variations in response to iridotomy.

*Comment:* Evidence is needed to evaluate the meaning of a shallow LACD in the presence of an 'open' angle on gonioscopy.

- There is currently no evidence in the literature supporting the standard use of provocative tests for angle closure. A negative provocative test does not exclude angle closure.

## References

1. Wilson JMG, Jungner F. Principles and Practice of screening for disease. Geneva: WHO, 1968 Public Health Papers No 34.
2. Quigley H, Broman A. The number of people with glaucoma worldwide in 2010 and 2020. *Br J Ophthalmol*, 2006;90:262-267.
3. Alsbirk PH. Anterior chamber depth and primary angle-closure glaucoma. I. An epidemiologic study in Greenland Eskimos. *Acta Ophthalmol (Copenh)* 1975;53:89-104.
4. Alsbirk PH. Early detection of primary angle-closure glaucoma. Limbal and axial chamber depth screening in a high risk population (Greenland Eskimos). *Acta Ophthalmol* 1988;66:556-564.
5. Lowe RF. Aetiology of the anatomical basis for primary angle-closure glaucoma. Biometrical comparisons between normal eyes and eyes with primary angle-closure glaucoma. *Br J Ophthalmol* 1970;54:161-169.
6. Devereux JG, Foster PJ, Baasanhu J, Uranchimeg D, Lee PS, Erdenbeleig T, Machin D, Johnson GJ, Alsbirk PH. Anterior chamber depth measurement as a screening tool for primary angle-closure glaucoma in an East Asian population. *Arch Ophthalmol* 2000;118:257-263.
7. Congdon NG, Quigley HA, Hung PT, Wang TH, Ho TC. Screening techniques for angle-closure glaucoma in rural Taiwan. *Acta Ophthalmol* 1996;74:113-119.
8. Thomas R, George T, Braganza A, Muliylil J. The flashlight test and Van Herick's test are poor predictors for occludable angles. *Aust N Z J Ophthalmol* 1996;24:251-256.
9. Foster PJ, Devereux J Glaucoma, Alsbirk PH, et al. Detection of gonioscopically occludable angles and primary angle-closure glaucoma by estimation of limbal chamber depth in Asians: Modified grading scheme. *Br J Ophthalmol* 2000;84:186-192.
10. Sihota R, Saxena R, Agarwal HC. Entropion uveae: early sphincter atrophy, signposting primary angle closure glaucoma? *Eur J Ophthalmol* 2004;14:290-297.
11. Foster PJ, Alsbirk PH, Baasanhu J, Munkhbayer D, Uranchimeg D, Johnson GJ. Anterior chamber depth in Mongolians: variation with age, sex, and method of measurement. *Am J Ophthalmol* 1997;124:53-60.
12. Congdon NG, Youlin Q, Quigley H, Hung PT, Wang TH, Ho TC, Tielsch JM. Biometry and primary angle-closure glaucoma among Chinese, white, and black populations. *Ophthalmology* 1997;104:1489-1495.
13. Aung T, Ang LP, Chan SP, Chew PT. Acute primary angle-closure: long-term intraocular pressure outcome in Asian eyes. *Am J Ophthalmol* 2001;131:7-12.
14. Robin AL, Arkell S, Gilbert SM, Gossens AA, Werner RP, Korshin OM. Q-switched neodymium-YAG laser iridotomy a field trial with a portable laser system. *Arch Ophthalmol* 1986;104:526-530.
15. Lim LS, Husain R, Gazzard G, Seah SK, Aung T. Cataract progression after prophylactic laser peripheral iridotomy: potential implications for the prevention of glaucoma blindness. *Ophthalmology* 2005;112:1355-1359.
16. Robin AL, Pollack IP. A comparison of neodymium: YAG and argon laser iridotomies. *Ophthalmology* 1984;91:1011-1016.
17. Schwartz GF, Steinmann WC, Spaeth GL, Wilson RP. Surgical and medical management

- of patients with narrow anterior chamber angles: comparative results. *Ophthalmic Surg* 1992;23:108-112.
18. Wilensky JT, Kaufman PL, Frohlichstein D, Gieser DK, Kass MA, Ritch R, et al. Follow-up of angle-closure glaucoma suspects. *Am J Ophthalmol* 1993;115:338-346.
  19. Alsbirk PH. Anatomical risk factors in primary angle-closure glaucoma. A ten-year follow-up survey based on limbal and axial anterior chamber depths in a high risk population. *Int Ophthalmol* 1992;16:265-272.
  20. Thomas R, George R, Parikh R, et al. Five year risk of progression of primary angle closure suspects to primary angle closure: a population based study. *Br J Ophthalmol* 2003;87:450-454.
  21. Lowe RF, Clark BA. Radius of curvature of the anterior lens surface. Correlations in normal eyes and in eyes involved with primary angle-closure glaucoma. *British Journal of Ophthalmology* 1973;57:471-474.
  22. Lowe RF, Clark BA. Posterior corneal curvature. Correlations in normal eyes and in eyes involved with primary angle-closure glaucoma. *Br J Ophthalmol* 1973;57:464-470.
  23. Lowe RF. Acute angle closure glaucoma and the crystalline lens. *Australian Journal of Ophthalmology* 1973;1:89-94.
  24. Alsbirk PH. Primary angle-closure glaucoma. Oculometry, epidemiology, and genetics in a high risk population. *Acta Ophthalmol Suppl* 1976;5-31.
  25. Alsbirk PH. Limbal and axial chamber depth variations. A population study in Eskimos. *Acta Ophthalmologica* 1986;64:593-600.
  26. Alsbirk PH. Primary angle-closure glaucoma. Oculometry, epidemiology, and genetics in a high risk population. *Acta Ophthalmol Suppl* 1976;5-31.
  27. Congdon NG, Youlin Q, Quigley H, Hung PT, Wang TH, Ho TC, et al. Biometry and primary angle-closure glaucoma among Chinese, white, and black populations. *Ophthalmology* 1997;104:1489-1495.
  28. Seah SK, Foster PJ, Chew PTK, Jap A, Oen F, Fam HB, et al. Incidence of acute primary angle-closure glaucoma in Singapore: An island-wide survey. *Arch Ophthalmol* 1997;115:1436-1440.
  29. Wong TY, Foster PJ, Seah SK, Chew PT. Rates of hospital admissions for primary angle closure glaucoma among Chinese, Malays, and Indians in Singapore. *Br J Ophthalmol* 2000;84:990-992.
  30. Hung PT, Chou LH. Provocation and mechanism of angle-closure glaucoma after iridectomy. *Arch Ophthalmol* 1979;97:1862-1864.
  31. Hyams SW, Friedman Z, Neumann E. Elevated intraocular pressure in the prone position. A new provocative test for angle-closure glaucoma. *Am J Ophthalmol* 1968;66:661-672.
  32. Friedman Z, Neumann E. Comparison of prone-position, dark-room, and mydriatic tests for angle-closure glaucoma before and after peripheral iridectomy. *Am J Ophthalmol* 1972;74:24-27.
  33. Harris LS, Galin MA. Prone provocative testing for narrow angle glaucoma. *Arch Ophthalmol* 1972;87:493-496.
  34. Wishart PK. Does the pilocarpine phenylephrine provocative test help in the management of acute and subacute angle closure glaucoma? *Br J Ophthalmol* 1991;75:284-287.
  35. Ishikawa H, Esaki K, Liebmann JM, Uji Y, Ritch R. Ultrasound biomicroscopy dark room provocative testing: a quantitative method for estimating anterior chamber angle width. *Japanese J Ophthalmol* 1999;43:526-534.





Poule Helge Alsbirk, an honored guest.



Ravi Thomas (left) and Remo Susanna (right)

## APPENDIX A

### DEVELOPMENT OF THE ANTERIOR CHAMBER

Lance Liu



Lance Liu

Although the precise mechanism of the formation of the anterior chamber angle is not completely known, it is thought to begin as a progressive deepening that initiates at month three to four of gestation and continues for possibly as long as four years after birth.<sup>1</sup> During this time, a number of major growth phases occurs: trabecular anlage formation (around the 15th week), differentiation into definitive structures (around the 24th week), specialisation of the definitive structures (around the 28th week), achievement of final components (birth) and final moulding of the chamber angle and the maturation of its cellular and extracellular constituents (one to eight years).<sup>2</sup> The main determinant in the configuration of the angle is the two-layered structure of the mesoderm of the ciliary body: the external muscular layer inserts into the spur and grows with the same rate as that of the corneoscleral mesoderm and internal fibrovascular layer giving rise to the ciliary processes and growing at the same growth rate as that of the neural ciliary and iris epithelium.<sup>3</sup> The ciliary body is within the uveal tissue at the same level as and faces the trabecular meshwork at five months gestation. The posterior movement of the ciliary body, including the muscle and processes, leads to progressive deepening of the angle and ends up posterior to the trabecular meshwork. This repositioning of the tissue is probably related to the differences in growth rate of the different tissues as the corneoscleral coat grows faster than the uveal tract during the last trimester, leading to a posterior migration of the ciliary body attachment from Schwalbe's line (fifth month) to the scleral spur (ninth month) and then to a location behind the scleral spur (postnatally).<sup>4</sup>

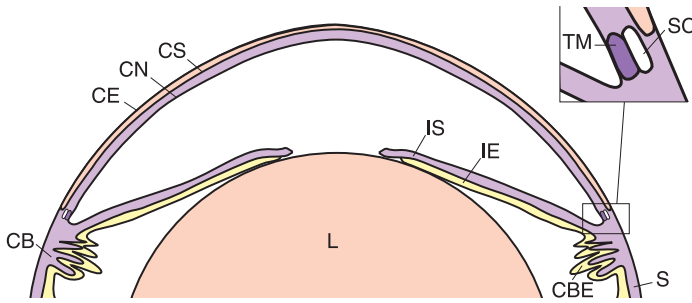
At birth, the angle is formed by the insertion of the iris at the level of the scleral spur, posterior to Schlemm's canal. The angle, at this time, has more uveal meshwork anterior to the ciliary muscle and lies in front of the scleral spur (1) which maybe seen as a membrane.<sup>4-7</sup> Maldevelopment of the irido-corneal angle can be the result of heredity or sporadic embarrassment.<sup>8</sup>

*Angle Closure and Angle Closure Glaucoma, pp. 65-69*

*edited by Robert N. Weinreb*

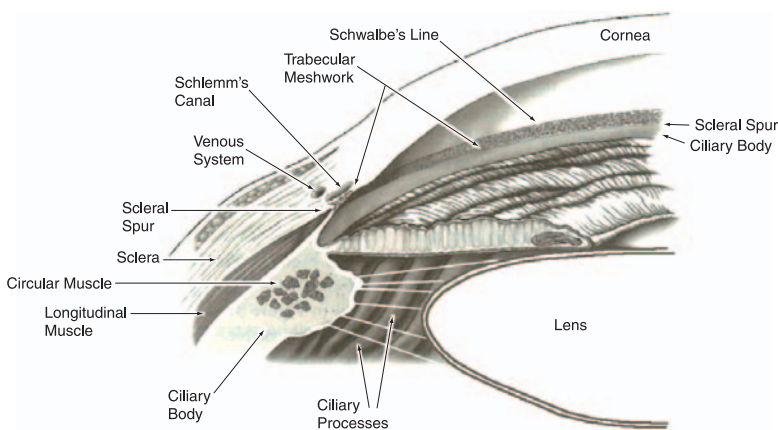
© 2006 Kugler Publications, The Hague, The Netherlands





*Fig. 1.* Neural ectoderm (yellow) moves through the periocular mesenchyme (purple) until it reaches the surface ectoderm (pink). The surface ectoderm becomes the corneal epithelium (CE). Periocular mesenchyme migrates between the surface ectoderm and lens, forming the corneal stroma (CS) and corneal endothelium (CN). In the mature eye, the anterior rim of the optic cup has moved centrally and forms the epithelia of the iris (IE) and ciliary body (CBE). Iris stroma (IS), corneal stroma (CS) and muscle of the ciliary body (CB), trabecular meshwork (TM) and Schlemm's canal (SC) are formed from periocular mesenchyme. Condensed periocular mesenchyme forms the sclera (S) and surrounds the posterior of the eye. (Reproduced with permission from Gould DB, Smith RS, John SW. Anterior segment development relevant to glaucoma. *Int J Dev Biol* 2004;48:1015-1029.)

In the normal adult eye, the iris inserts into the ciliary body, above which the sclera can be visualized as the scleral spur. The trabecular meshwork runs from the scleral spur superiorly to Schwalbe's line, the internal boundary between the sclera and the cornea. The posterior half of the trabecular meshwork becomes pigmented as the eye ages. Behind the posterior third of the trabecular meshwork is Schlemm's canal, the opening through which the aqueous leaves the anterior chamber.<sup>1</sup>



*Fig. 2.* (From Tasman W, Jaeger E. *The Wills Eye Hospital Atlas of Clinical Ophthalmology*. Philadelphia: Lippincott Williams & Wilkins, 2001 Ch.3.)

### Anterior chamber depth and the lens

During the first year of life, the anterior chamber depth changes linearly and the lens thickness is essentially constant.<sup>9</sup> The eye continues to grow from age six to age 15 as the axial length, anterior chamber depth, and vitreous chamber depth increase.<sup>10</sup>

In normal adult eyes, the anterior chamber depth decreases with age and occurs in both sexes with an accelerated decrease between the fourth and fifth decades in females.<sup>11</sup> Women have shallower anterior chamber depths<sup>12</sup> and more pronounced age-related change in anterior chamber depth than men.<sup>12,13</sup> The ratio of anterior chamber depth to axial length was smaller in females than in males after the fifth decade.<sup>11</sup>

The decreasing anterior chamber depth with age is seen in various populations.<sup>14</sup> Eskimos seem to have shallower anterior chambers than other racial groups,<sup>15</sup> but the Chinese do not differ, on a population basis, from white and black groups.<sup>16</sup>

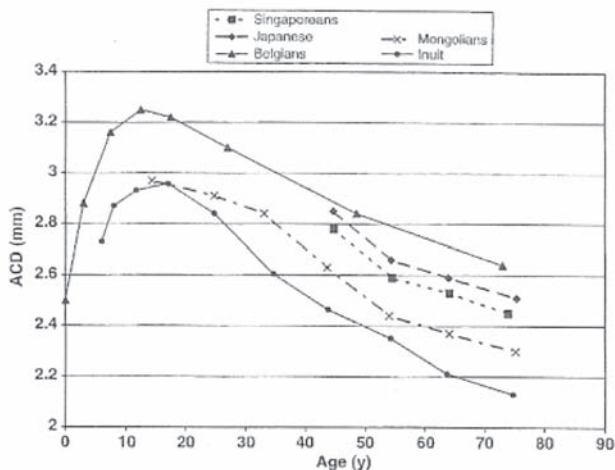


Fig. 3. Variation of mean ACD with age in five ethnic groups. All studies employed Haag-Streit optical pachymetry and calculated ACD by subtracting corneal thickness. (Reproduced with permission from Foster PJ. The epidemiology of primary angle-closure and associated glaucomatous optic neuropathy. *Semin Ophthalmol* 2002;17:50-58.)

One factor that may contribute to this is that the lens grows with age.<sup>11,17,18</sup> This growth appears to be confined to the anterior portion of the lens.<sup>19</sup> The lens thickness increases at an accelerated rate between the fourth and sixth decades, then does not increase for about a decade, before finally increasing again but at a slower pace.<sup>20</sup> The anterior chamber depth, however, appears to continue to decrease at a constant rate over this time.

## Iris

Spaeth found that in the adult (compared to a child), the angular approach is narrower, there are less iris processes, pigmentation of the trabeculum is more and the peripheral curvature of the iris is more curved.<sup>6</sup>

Comparing under 31 year olds to 71 year olds and older, Ochiai *et al.* found that the incidence of forward bowing of the iris increases as the iridocorneal angle is significantly narrower and the distance between the apex of the angle and the scleral spur is significantly less in the latter group.<sup>21</sup>

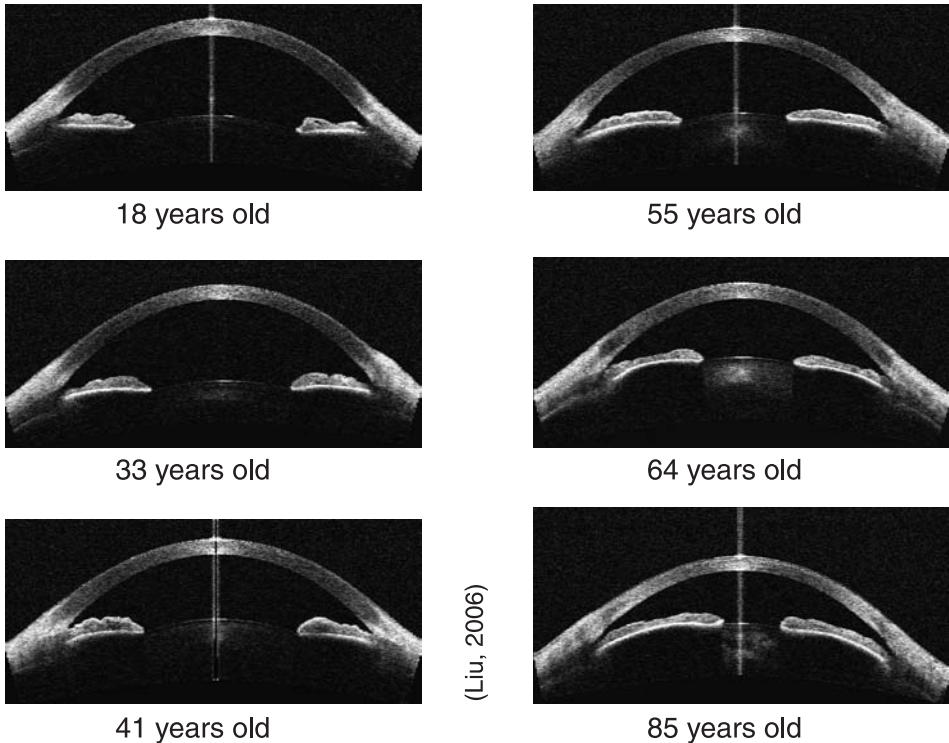


Fig. 4. Anterior segment OCTs showing the decrease in anterior chamber depth and the 'forward bowing of the iris' with age. (Courtesy of Dr Lance Liu, FRANZCO.)

Amongst different populations, the iris joins the scleral wall more anteriorly in Asians, slightly more posteriorly in Afro-Americans, and most posteriorly in Caucasians. The anterior chamber tends to be narrower in females and becomes narrower with increasing age in all ethnic groups. However, there is no significant difference found between the angle width of these three groups.<sup>22</sup>

## References

1. Tripathi BJ, Tripathi RC. Embryology of the anterior segment of the human eye. In: Ritch R et al (eds). *The glaucoma*, vol 1. St. Louis: CV Mosby, 1989: Ch 1.
2. Reme C, d'Épinay SL. Periods of development of the normal human chamber angle. *Doc Ophthalmol* 1981;51:241-268.
3. Barishak YR. The development of the angle of the anterior chamber in vertebrate eyes. *Doc Ophthalmol* 1978;45:329-360.
4. Anderson DR. The development of the trabecular meshwork. *Trans Am Ophthalmic Soc* 1981;79:458-184.
5. Spaeth G. Gonioscopy: Uses old and new. The inheritance of occludable angle ophthalmology. *Ophthalmology* 1978;85:232.
6. Spaeth G. The normal development of the human anterior chamber angle: A new system of descriptive grading. *Trans Ophthalmol Soc UK* 1971;91:709-713.
7. Barkan O. Pathogenesis of congenital glaucoma. Gonioscopic and anatomic observation of the angle and the anterior chamber on the normal eye and in congenital glaucoma. *Am J Ophthalmol* 1955;40:1-11.
8. Jerndt T, et al. *Goniodysgenesis: A new perspective in glaucoma*, Copenhagen: Scriptor, 1978.
9. Pennie FC, Wood IC, Olsen C, White S, Charman WN. A longitudinal study of the biometric and refractive changes in full-term infants during the first year of life. *Vision Res* 2001;41:2799-2810.
10. Zadnik K, Mutti DO, Mitchell GL, Jones LA, Burr D, Moeschberger ML. Normal eye growth in emmetropic schoolchildren. *Optom Vis Sci* 2004;81:819-828.
11. Lim KJ, Hyung SM, Youn DH. Ocular dimensions with aging in normal eyes. *Korean J Ophthalmol* 1992;6:19-31.
12. Foster PJ, Alsbirk PH, Baahhanu J, et al. Anterior chamber depth in Mongolians. Variation with age, sex and method of measurement. *Am J Ophthalmology* 1997; 124:53-60.
13. Alsbirk PH. Primary angle-closure glaucoma. Oculometry, epidemiology, and genetics in a high risk population. *Acta Ophthalmol (Copenh)* 1976;54:5-31.
14. Foster PJ. The Epidemiology of primary angle closure and associated glaucomatous optic neuropathy. *Seminar Ophthalmol* 2002;17:50-58.
15. Wojciechowski R, Congdon N, Anninger W, Teo Broman A. Age, gender, biometry, refractive error, and the anterior chamber angle among Alaskan Eskimos. *Ophthalmology* 2003;110:365-375.
16. Congdon NG, Youlin Q, Quigley H, Hung PT, Wang TH, Ho TC, Tielsch JM. Biometry and primary angle-closure glaucoma among Chinese, white, and black populations. *Ophthalmology* 1997;104:1489-1495.
17. Duncan G, Wormstone IM, Davies PD. The aging human lens: structure, growth, and physiological behaviour. *Brit J Ophthalmol* 1997;81:818-823.
18. Spencer RP. Change in weight of the human lens with age. *Ann Ophthalmol* 1976;8:440-441.
19. Strenk SA, Strenk LM, Semmlow JL, DeMarco JK. Magnetic resonance imaging study of the effects of age and accommodation on the human lens cross-sectional area. *Invest Ophthalmol Vis Sci* 2004;45:539-545.
20. Markowitz SN, Morin JD. Angle-closure glaucoma: relation between lens thickness, anterior chamber depth and age. *Can J Ophthalmol* 1984;19:300-302.
21. Ochiai H, Chihara E, Chuman H, Sawada A, Akita J. Age and increased incidence of "forward bowing" of the iris in normal eyes. *J Glaucoma* 1998;7:408-412.
22. Oh YG, Minelli S, Spaeth GL, Steinman WC. The anterior chamber angle is different in different racial groups: a gonioscopic study. *Eye* 1994;8:104-108.



Lisandro Sakata, Lance Liu, Aiko Iwase, Jeffrey Liebmann, Ming-Guang He, Kuldev Singh, John Thygesen (left to right).



Erik Greve (Executive Vice President).

## APPENDIX B

### ULTRASOUND BIOMICROSCOPY

Jeffrey Liebmann



Jeffrey Liebmann

Ultrasound biomicroscopy (UBM) is performed in the supine position. A 20-mm eye cup is inserted between the lids and holds the methylcellulose or normal saline coupling medium. After insertion of the probe into the coupling medium, the real-time image is displayed on a video monitor and can be stored on videotape for later analysis. Although good qualitative information can be obtained by inexperienced examiners, acquisition of highly reproducible distance measurements is strongly dependent on examiner technique and experience. The configuration of the anterior segment and the relative proportions of structures in images obtained by scanning depend on the plane of section, any degree of tilt from perpendicular in the scanning probe, and the distance from the center of the anterior chamber. Room illumination, fixation, and accommodative effort affect anterior segment anatomy and should be held constant, particularly when quantitative information is being gathered.



Mani Baskaran (left), Jonathan Crowston (center), and Kenji Kashiwagi (right).



Augusto Azuara-Blanco (left), Martin Wand (center), and Carlo Traverso (right).



## APPENDIX C

### DEVICES FOR SCREENING FOR ANGLE CLOSURE

M. Baskaran

Below is a list of several recently developed screening devices. There is little published in the field of screening for angle closure using these recently developed instruments. However, these may play a role in PACG screening and management, and therefore we discuss them here.

- IOLMaster (Zeiss). This instrument measures central anterior chamber depth, keratometry and axial length using the combination of partial coherence biometry (infrared light) and optical method.
- Pentacam (Oculus) uses other methods for Central ACD measurement. While the optical pachymetry can be performed at the slit lamp the Pentacam has the advantage of rotating Scheimpflug photography, which may offer more insight into angle structures.
- SPAC – Scanning Peripheral Anterior Chamber depth analyzer (Takagi). This instrument obtains 21 rapid slit photographs of the central and peripheral anterior chamber using optical method and creates an iris anterior surface contour using the measurements. They are graded numerically and categorically compared to a sample database to provide an empirical risk assessment.<sup>1-3</sup> SPAC appears to identify a high proportion of those with narrow angles. Using the methods described, the AUC for detecting narrow angles was described as excellent ranging between 0.97 and 0.98 in Japanese patients. Its usefulness in screening awaits further validation.
- ASOCT – Anterior Segment Optical Coherence Tomography (Visante, Zeiss). This utilizes infrared light to image the angle and the anterior chamber in real time,<sup>4</sup> but not the ciliary body as in UBM. A comparison between UBM and ASOCT was described recently compared to gonioscopy.<sup>5</sup> Recent early research indicates that the AS-OCT identifies a high proportion of subjects felt to be narrow or closed on gonioscopy,<sup>6</sup> however, the device identified more subjects as having closed angles than gonioscopy. Further research will be needed to determine the role of AS-OCT in screening.



All the instruments except the ASOCT rely on light in the visible spectrum. Theoretically, as with gonioscopy, visible light may affect the angle status during examination.

## References

1. Kashiwagi K, Kashiwagi F, Toda Y, Osada K, Tsumura T, Tsukahara S. A newly developed peripheral anterior chamber depth analysis system: principle, accuracy, and reproducibility.
2. Kashiwagi K, Abe K, Tsukahara S. Quantitative evaluation of changes in anterior segment biometry by peripheral laser iridotomy using newly developed scanning peripheral anterior chamber depth analyser. *Br J Ophthalmol* 2004; 88: 1036-1041.
3. The development of the angle of the anterior chamber in vertebrate eyes. *Doc Ophthalmol* 1978;1:329-360.
4. Leung CK, Chan WM, Ko CY, Chui SI, Woo J, Tsang MK, Tse RK. Visualization of anterior chamber angle dynamics using optical coherence tomography. *Ophthalmology* 2005;112: 980-984.
5. Radhakrishnan S, Goldsmith J, Huang D, Westphal V, Dueker DK, Rollins AM, Izatt JA, Smith SD. Comparison of optical coherence tomography and ultrasound biomicroscopy for detection of narrow anterior chamber angles. *Arch Ophthalmol* 2005;123:1053-1059.
6. Spaeth GL. The normal development of the human anterior chamber angle: a new system of descriptive grading. *Trans Ophthalmol Soc UK* 1971;91:709-739.

## APPENDIX D

### COST EFFECTIVENESS (CEA) OF SCREENING FOR PRIMARY ANGLE CLOSURE GLAUCOMA



Augusto Azuara Blanco

Augusto Azuara Blanco and Jennifer Yip

#### Overview

Health economics is concerned with the allocation of scarce resources in order to maximize health benefits. This area has become increasingly important as there is greater demand with new technologies, demographic changes and increased public awareness. Economic evaluation allows us to compare alternatives based on both costs and consequences and thus assists decision makers in making difficult choices. There are four main types of economic evaluations which differ mainly in their assessment of consequences.

- Cost minimization analysis – comparing difference in costs between two interventions with identical outcomes.
- Cost benefit analysis – outcomes in terms of dollars, translated by methods such as willingness-to-pay; outcome is valued in monetary terms.
- Cost effectiveness analysis – outcomes in clinical or natural terms, *e.g.*, number of deaths averted, number of cases detected.
- Cost utility analysis – outcome is valued in terms of change in ‘utility’ combined with the duration of this change. A change in utility aims to approximate a change in the patient’s global wellbeing and its combination with length of time provides a quality of life assessment, *e.g.*, Quality Adjusted Life Years (QALYs). This is the most useful analysis as it is the one that is likely to provide outcomes of importance to individuals. Each of the different stages of the disease (*e.g.*, PAC, PACG and blindness) may have a negative impact on the quality of life (QoL). From a CUA, the impact of the disease on the QoL would be measured using utility values. There are several methods that can be used, such as discrete choice, time-trade off, standard gamble, etcetera.

*Angle Closure and Angle Closure Glaucoma*, pp. 75-79

edited by Robert N. Weinreb

© 2006 Kugler Publications, The Hague, The Netherlands

A screening program not only needs to be effective, but also cost-effective. The opportunity cost of initiating a PACG screening programme needs to be considered, as well as whom to screen and how often. As several screening strategies may be possible, the most likely method of screening to be considered cost-effective should be identified. There are examples of such analysis for open-angle glaucoma (OAG) but, as far as we know, not for PACG. A cost-effectiveness study in Canada, using a hypothetical population cohort aged 40-79 years, of screening for OAG using optic disc assessment and IOP, followed by perimetry if abnormal, resulted in an estimated cost of \$C 100,000 per year of blindness prevented. For a different age cohort, 65-79 years, a cost of \$C 42,000 per year of blindness prevented was estimated.<sup>1</sup> In 1997, Tuck and Crick in the UK concluded that OAG screening of people over 40 years could be justifiable in the UK, provided that it is worth more than \$ 850 to detect a new case. This evaluation was based on an economic model of a potential screening program, targeted at all adults over 40 in optometric practice, using a combination of three tests: level of IOP, optic disc assessment by ophthalmoscopy and visual field measurement using semi-automated perimetry. This model did not include any measure of effectiveness of treatment or benefit from early detection.<sup>2</sup>

Currently, there are no economic evaluations published relating to PACG. We will focus on steps involved in a CEA.

## Perspective

The costs identified and evaluated in any study is dependent on which viewpoint is taken. For example, the lost wages would matter from a patients' perspective but not from a healthcare providers' perspective. In general, a societal viewpoint is taken as this tends encompass most aspects.

## Choice of clinical and economic outcome

This is dependent on the objective or outcome of the clinical intervention. An alternative must also be chosen for comparison. In screening for PACG, there are various choices:

- Number of cases detected – in the first stage of the screening program, this is the primary objective, but case must also be clearly defined, *e.g.*, PACS, PAC or PACG, and is dependent on what the screening program is designed to detect. An alternative screening tool or program must also be identified for comparison in order to generate an outcome measure such as an incremental cost effectiveness ratio (*e.g.*, AS-OCT vs SPAC).
- Number of cases prevented – one of the aims of screening for 'occludable' angles is prevention of glaucoma and visual impairment, however, here we are mixing whether screening can detect a case with whether intervention

can prevent disease. This will require information on the natural history of the disease, *i.e.*, whether the screened entity will lead to glaucoma and subsequent visual loss, and also the effectiveness of the intervention used.

- Cases of blindness prevented – Reduction in morbidity is the usual final health outcome for a screening program. However, time and resource constraints is unlikely to allow a study to directly measure this as an outcome, therefore modeling techniques may be required (see below). Effort should be made to relate intermediate outcomes as described above with this final outcome if possible.

## Choice of methods

Cost data for economic evaluations can be collected prospectively in or alongside an ongoing trial. This would provide individualized information regarding cost and outcome, and thus easier to analyze and interpret. The alternative is economic modeling based on available data from publications, and may be a necessary adjunct due to constraints on a clinical trial or study.

## Direct measurements

Costs collected during a screening study requires careful identification of the resources used. One type of cost classification is direct, indirect and intangible.

*Direct costs* of a screening program are those due to resources consumed (both medical and non-medical) with the provision of the activity. For a study on screening for PACG, this would include capital costs, overhead costs, salaries, transport costs etcetera (this list is not exhaustive). These can be estimated by actual resources used in a trial.

*Indirect costs* are costs to society as a result of participating in the screening, *e.g.*, days off work, lost leisure time – activities that the participant would otherwise be involved in if not being screened. These are usually quantifiable in monetary terms, and can be obtained by a questionnaire applied to study patients. If a companion or carer comes with the participant to screening, then their time and cost must also be recorded.

*Intangible costs* are difficult to quantify in monetary terms and include concepts such as pain and suffering. This is difficult to measure but may be important for cases of acute angle closure.

The timeframe of the screening program must also be accounted for. Therefore costs accrued in the future needs to be discounted, *i.e.*, a dollar spent today is worth more than in the future – this is the concept of time preference. This is usually 3-5%.

It should be remembered that cost data collected with a trial is likely to be higher than actual costs as techniques and equipment use may be different

from standard clinical practice, and examinations will take more time. Costs could be overestimated, unless a pragmatic trial is carried out, where the study conditions are as close to real life as possible. As the study population may be selected and different from the target population, results may have issues of generalizability. In addition, as mentioned above, an intermediate outcome may be measured, in which case the link with the final health outcome – blindness will require modeling. Data on the overall costs of the disease would also need to be gathered.

### **Modeling techniques for CEA**

There are several ways to produce economic models, including decision analysis, statistical and epidemiological methods. Another method that could be applied to screening for PACG is a Markov model.

A Markov model of cost-effectiveness of screening for PACG would describe the pathway of individuals from initial screening to the costs and consequences for those who receive correct or incorrect diagnoses, and of non-diagnosis for those who either decline or are not selected for screening. A Markov model is a very simple concept but it can be very complex to run.

Typically, Markov models have states (*e.g.*, PACS, PAC, PACG, blindness, death) in which individuals stay for a period of time called ‘cycle’ (*e.g.*, one year). In those cycles, the model will assign costs and benefits for each individual according to different interventions. At the end of each cycle, individuals can remain in the same state or move to a different one. The probabilities of moving from one state to another are called transition probabilities.

For a Markov model you can use the total population at risk (*e.g.*, all Asians aged 60 or over) or, to make it simpler, you can use a cohort of patients (*e.g.*, those Asians who are 60 years only).

For PACG, for example, with a Markov model could evaluate the estimated costs and outcomes over a selected period of time of a cohort of patients for different screening strategies adopted, compared with the estimated costs and outcomes of a similar cohort of patients not screened.

Markov models would use data on all variables of a screening program indicated above, including prevalence/incidence, diagnostic accuracy of each possible test or combination of tests, acceptability and attendance rate, potential harm, costs of alternative screening strategies, effect of earlier diagnosis and early treatment on the progression of the disease and prevention of blindness (needed data on natural history and long-term effects of interventions).

A CEA model could be applied for different intervals of screening (*e.g.*, every one, five or ten years).

The disadvantage of economic modeling is that inferences are made on based on different types and population based summary data, and the association between cause and effect can be erroneous, therefore the validity of the estimate should be verified if possible.

## Sensitivity analysis

Economic evaluations present the degree of uncertainty or imprecision in the study with sensitivity analysis. This is simply the process to assess how robust the conclusions are by varying key parameters measured or modeled over a specified to range and estimate the effects on the final outcome. If there are no changes in results by varying these underlying estimates, then we would have more confidence in the results obtained. This is often applied to economic models where point estimates are used. When data is collected with a trial, it is possible to obtain information on sampling variation and use statistical tests instead.


## Presentation of results

The outcome of a CEA is in the form of cost per outcome. The results of an economic model could be presented in terms of a cost-consequence analysis (*e.g.*, number of persons screened, number of cases of PACG detected per year, cases of blindness prevented). Results could also be presented a incremental cost-effectiveness ratios (ICER), *e.g.*, incremental cost per case of blindness prevented. This measure is a ratio of the difference in costs divided by the difference in effectiveness between two alternative strategies. Results can be read as how much society will have to pay for an extra unit of effectiveness.

There are other issues to consider: A decision to establish a screening program can have considerable impact on services. Adequate staffing and facilities for testing, diagnosis, treatment and programme management need to be available. The services required depend on the stage of disease worth detecting and the frequency of the screening interval.

## References

1. Boivin JF, McGregor M, Archer C. Cost effectiveness of screening for primary open angle glaucoma. *J Med Screen* 1996;3:154-163.
2. Tuck MW, Crick RP. The cost-effectiveness of various modes of screening for primary open angle glaucoma. *Ophthalmic Epidemiol* 1997;4:3-17.



Ted Krupin (left) making a point with Murray Fingeret (right).



Makoto Aihara (left) and Goji Tomita (right).





Angle Closure Consensus co-Chairs conferring over a consensus point: Paul Foster (left), David S. Friedman (center), and Tin Aung (right).



Tony Wells (left), Jonathan Crowston (center), and Makoto Aihara (right).





Poule Helge Alsbirk (left) and Caroline Geijssen (right) discussing the consensus agenda.



Aiko Iwase (left) and Jeffrey Liebmann (right).




Douglas Anderson.



Kenji Kashiwagi (left) and George Spaeth (right).



Kuldev Singh (left) and John Thygesen (right).



Carlo Traverso.




Harry Quigley (left) and Peng T. Khaw (right).



Young Kwon (left), Gus Gazzard (center), and Ravi Thomas (right).




Franz Grehn (left) and Hans Lemij (right).



Paul Healey (left) and Rupert Bourne (right).





Peter Shah (left) and Winnie Nolan (right).



Robert Fechtner (left), David Greenfield (center), and Greg Skuta (right).




Stuart Graham (left) and Thierry Zeyen (right).



Tony Wells, Ted Krupin, Daniel Grigera (front row, left to right).



Tony Hommer.



Franz Grehn (left), Makoto Araie (center) and Roberto Carassa (right).





Nehru Gupta.




John Salmon (left) and Carlo Traverso (right).



Winnie Nolan.



Remo Susanna.



Keith Martin (left) and Rupert Bourne (right) relaxing at a break.



Patricia Khu (left), and Ivana Liehneova (right).



Murray Fingeret (left), Ravi Thomas (center), and Mike Patella (right).



Scott Smith (left) and Ming-Guang He (right).



Daniel Grigera.



Robert Fechtner.



Ronnie George.



Robert N. Weinreb (left) and Ravi Thomas (right)





Anders Heijl (left) and Ravi Thomas (right)



# GLOSSARY

**AC:** Anterior chamber

**ACD:** Anterior chamber depth

**ALPI:** Argon laser peripheral iridoplasty

**AOD:** Angle opening distance (from ultrasound biomicroscopy). This is the length of a line drawn from the corneal endothelial surface to the iris at a fixed distance from the scleral spur. The most commonly quoted distance is 500 microns, and this is referred to as the AOD500.

**ITC:** iridotrabecular contact

**LPI:** Laser peripheral iridotomy

**PAC:** Primary angle closure:

**PACG:** Primary angle closure glaucoma

**PAS:** peripheral anterior synechiae

**OCT:** Optical coherence tomography

**UBM:** Ultrasound biomicroscopy

# INDEX OF AUTHORS

Alsbirk, P.H., 55  
Aung, T., xiii, 27  
Azuara Blanco, A., 75  
Baskaran, M., 73  
Foster, P., xiii, 1  
Friedman, D.S., xiii, 55  
Gazzard, G., 55  
Greve, E.L., xi  
He, M., 1  
Lam, D., 37  
Liebmann, J., 1, 71  
Liu, L., 65  
Nolan, W., 37  
Quigley, H., 21  
RojanaPongpun, P., 27  
Ritch, R., 37  
Salmon, J., 27  
Thomas, R., 55  
Weinreb, R.N., xi, xiii  
Yamamoto, T., 21  
Yip, J. 75