

PREFERRED PRACTICE PATTERN®



Primary Angle Closure

Secretary for Quality of Care
Stephen D. McLeod, MD

Academy Staff
Nicholas P. Emptage, MAE
Doris Mizuiri
Laurie Bagley, MLS
Flora C. Lum, MD

Medical Editor: Susan Garratt
Design: Socorro Soberano

Approved by: Board of Trustees
September 18, 2015

Copyright © 2015 American Academy of Ophthalmology®
All rights reserved

AMERICAN ACADEMY OF OPHTHALMOLOGY and PREFERRED PRACTICE PATTERN are registered trademarks of the American Academy of Ophthalmology. All other trademarks are the property of their respective owners.

Preferred Practice Pattern® guidelines are developed by the Academy's H. Dunbar Hoskins Jr., MD Center for Quality Eye Care without any external financial support. Authors and reviewers of the guidelines are volunteers and do not receive any financial compensation for their contributions to the documents. The guidelines are externally reviewed by experts and stakeholders before publication.



GLAUCOMA PREFERRED PRACTICE PATTERN[®] DEVELOPMENT PROCESS AND PARTICIPANTS

The **Glaucoma Preferred Practice Pattern[®] Panel** members wrote the Primary Angle Closure Preferred Practice Pattern[®] guidelines (“PPP”). The PPP Panel members discussed and reviewed successive drafts of the document, meeting in person twice and conducting other review by e-mail discussion, to develop a consensus over the final version of the document.

Glaucoma Preferred Practice Pattern Panel 2014–2015

Bruce E. Prum, Jr., MD, Co-chair
 Leon W. Herndon, Jr., MD
 Sayoko E. Moroi, MD, PhD
 Steven L. Mansberger, MD, MPH, Methodologist
 Joshua D. Stein, MD, MS, American Glaucoma Society Representative
 Michele C. Lim, MD
 Lisa F. Rosenberg, MD
 Steven J. Gedde, MD
 Ruth D. Williams, MD, Co-chair

The **Preferred Practice Patterns Committee** members reviewed and discussed the document during a meeting in April 2015. The document was edited in response to the discussion and comments.

Preferred Practice Patterns Committee 2015

Robert S. Feder, MD, Chair
 Timothy W. Olsen, MD
 Randall J. Olson, MD
 Bruce E. Prum, Jr., MD
 C. Gail Summers, MD
 Ruth D. Williams, MD
 David C. Musch, PhD, MPH, Methodologist

The Primary Angle Closure PPP was then sent for review to additional internal and external groups and individuals in July 2015. All those who returned comments were required to provide disclosure of relevant relationships with industry to have their comments considered (indicated with an asterisk below). Members of the PPP Panel reviewed and discussed these comments and determined revisions to the document.

Academy Reviewers

Board of Trustees and Committee of Secretaries*
 Council*
 General Counsel*
 Ophthalmic Technology Assessment Committee
 Glaucoma Panel*
 Basic and Clinical Science Course Section 10
 Subcommittee
 Practicing Ophthalmologists Advisory Committee
 for Education*

Invited Reviewers

American Academy of Family Physicians
 American College of Physicians*
 American College of Surgeons
 American Glaucoma Society*
 American Ophthalmological Society*
 American Society of Cataract & Refractive
 Surgery

Association of University Professors of
 Ophthalmology
 Canadian Ophthalmological Society
 Consumer Reports Health Choices
 European Glaucoma Society*
 European Society of Cataract and Refractive
 Surgeons
 Glaucoma Research Foundation*
 Greek Glaucoma Society*
 International Society of Refractive Surgery
 National Eye Institute*
 National Medical Association
 National Partnership of Women and Families
 Outpatient Ophthalmic Surgery Society
 Women in Ophthalmology*
 James D. Brandt, MD
 Donald L. Budenz, MD, MPH
 Lawrence M. Hurvitz, MD*
 Paul P. Lee, MD, JD



FINANCIAL DISCLOSURES

In compliance with the Council of Medical Specialty Societies' Code for Interactions with Companies (available at www.cmss.org/codeforinteractions.aspx), relevant relationships with industry are listed. The Academy has Relationship with Industry Procedures to comply with the Code (available at www.aao.org/about-preferred-practice-patterns). A majority (56%) of the members of the Glaucoma Preferred Practice Pattern Panel 2014–2015 had no related financial relationship to disclose.

Glaucoma Preferred Practice Pattern Panel 2014–2015

Steven J. Gedde, MD: Alcon Laboratories, Inc., Allergan – Consultant/Advisor

Leon W. Herndon, Jr., MD: Alcon Laboratories, Inc. – Consultant/Advisor, Lecture fees; Glaukos Corporation – Lecture fees

Michele C. Lim, MD: No financial relationships to disclose

Steven L. Mansberger, MD, MPH: Alcon Laboratories, Inc., Allergan, Glaukos Corporation – Consultant/Advisor

Sayoko E. Moroi, MD, PhD: No financial relationships to disclose

Bruce E. Prum, Jr., MD: No financial relationships to disclose

Lisa F. Rosenberg, MD: No financial relationships to disclose

Joshua D. Stein, MD, MS: No financial relationships to disclose

Ruth D. Williams, MD: Allergan – Consultant/Advisor

Preferred Practice Patterns Committee 2015

Robert S. Feder, MD: No financial relationships to disclose

David C. Musch, PhD, MPH: Glaukos Corporation, InnFocus, LLC, Ivantis, Inc. – Consultant/Advisor (Data & Safety Monitoring Board member for clinical trials)

Timothy W. Olsen, MD: No financial relationships to disclose

Randall J. Olson, MD: No financial relationships to disclose

Bruce E. Prum, Jr., MD: No financial relationships to disclose

C. Gail Summers, MD: No financial relationships to disclose

Ruth D. Williams, MD: Allergan – Consultant/Advisor

Secretary for Quality of Care

Stephen D. McLeod, MD: No financial relationships to disclose

Academy Staff

Laurie Bagley: No financial relationships to disclose

Nicholas P. Emptage, MAE: No financial relationships to disclose

Susan Garratt: No financial relationships to disclose

Flora C. Lum, MD: No financial relationships to disclose

Doris Mizuiri: No financial relationships to disclose

The disclosures of relevant relationships to industry of other reviewers of the document from January to August 2015 are available online at www.aao.org/ppp.



TABLE OF CONTENTS

OBJECTIVES OF PREFERRED PRACTICE PATTERN GUIDELINES	P6
METHODS AND KEY TO RATINGS	P7
HIGHLIGHTED FINDINGS AND RECOMMENDATIONS FOR CARE	P8
INTRODUCTION	P9
Disease Definition	P9
Disease Classification and Clinical Findings Characteristic of Angle Closure	P9
Primary Angle-Closure Suspect	P9
Primary Angle Closure and Primary Angle-Closure Glaucoma	P10
Acute Angle-Closure Crisis	P10
Plateau Iris Configuration and Syndrome	P10
Patient Population	P10
Clinical Objectives	P10
BACKGROUND	P11
Prevalence	P11
Risk Factors	P12
Demographic Characteristics	P12
Ocular Features	P12
Natural History	P12
CARE PROCESS	P12
Patient Outcome Criteria	P12
Diagnosis	P12
History	P13
Physical Examination	P13
Differential Diagnosis	P19
Management	P19
Goals	P19
Primary Angle-Closure Suspect	P19
Primary Angle Closure and Primary Angle-Closure Glaucoma	P19
Surgery and Postoperative Care	P20
Acute Angle-Closure Crisis	P21
Plateau Iris Configuration and Syndrome	P23
Follow-up Evaluation	P23
Provider and Setting	P24
Counseling and Referral	P24
Socioeconomic Considerations	P24
APPENDIX 1. QUALITY OF OPHTHALMIC CARE CORE CRITERIA	P26
APPENDIX 2. INTERNATIONAL STATISTICAL CLASSIFICATION OF DISEASES AND RELATED HEALTH PROBLEMS (ICD) CODES	P28
APPENDIX 3. ALGORITHM FOR THE MANAGEMENT OF PATIENTS WITH ACUTE ANGLE-CLOSURE CRISIS	P29
APPENDIX 4. LITERATURE SEARCHES FOR THIS PPP	P30
SUGGESTED REFERENCE TEXTS	P31
RELATED ACADEMY MATERIALS	P31
REFERENCES	P32



OBJECTIVES OF PREFERRED PRACTICE PATTERN® GUIDELINES

As a service to its members and the public, the American Academy of Ophthalmology has developed a series of Preferred Practice Pattern® guidelines that **identify characteristics and components of quality eye care**. Appendix 1 describes the core criteria of quality eye care.

The Preferred Practice Pattern® guidelines are based on the best available scientific data as interpreted by panels of knowledgeable health professionals. In some instances, such as when results of carefully conducted clinical trials are available, the data are particularly persuasive and provide clear guidance. In other instances, the panels have to rely on their collective judgment and evaluation of available evidence.

These documents provide guidance for the pattern of practice, not for the care of a particular individual. While they should generally meet the needs of most patients, they cannot possibly best meet the needs of all patients. Adherence to these PPPs will not ensure a successful outcome in every situation. These practice patterns should not be deemed inclusive of all proper methods of care or exclusive of other methods of care reasonably directed at obtaining the best results. It may be necessary to approach different patients' needs in different ways. The physician must make the ultimate judgment about the propriety of the care of a particular patient in light of all of the circumstances presented by that patient. The American Academy of Ophthalmology is available to assist members in resolving ethical dilemmas that arise in the course of ophthalmic practice.

Preferred Practice Pattern® guidelines are not medical standards to be adhered to in all individual situations. The Academy specifically disclaims any and all liability for injury or other damages of any kind, from negligence or otherwise, for any and all claims that may arise out of the use of any recommendations or other information contained herein.

References to certain drugs, instruments, and other products are made for illustrative purposes only and are not intended to constitute an endorsement of such. Such material may include information on applications that are not considered community standard, that reflect indications not included in approved U.S. Food and Drug Administration (FDA) labeling, or that are approved for use only in restricted research settings. The FDA has stated that it is the responsibility of the physician to determine the FDA status of each drug or device he or she wishes to use, and to use them with appropriate patient consent in compliance with applicable law.

Innovation in medicine is essential to ensure the future health of the American public, and the Academy encourages the development of new diagnostic and therapeutic methods that will improve eye care. It is essential to recognize that true medical excellence is achieved only when the patients' needs are the foremost consideration.

All Preferred Practice Pattern® guidelines are reviewed by their parent panel annually or earlier if developments warrant and updated accordingly. To ensure that all PPPs are current, each is valid for 5 years from the "approved by" date unless superseded by a revision. Preferred Practice Pattern guidelines are funded by the Academy without commercial support. Authors and reviewers of PPPs are volunteers and do not receive any financial compensation for their contributions to the documents. The PPPs are externally reviewed by experts and stakeholders, including consumer representatives, before publication. The PPPs are developed in compliance with the Council of Medical Specialty Societies' Code for Interactions with Companies. The Academy has Relationship with Industry Procedures (available at www.aao.org/about-preferred-practice-patterns) to comply with the Code.

Appendix 2 contains the International Statistical Classification of Diseases and Related Health Problems (ICD) codes for the disease entities that this PPP covers. Appendix 3 has an algorithm for the management of patients with acute angle-closure crisis (AACC). The intended users of the Primary Angle Closure PPP are ophthalmologists.



METHODS AND KEY TO RATINGS

Preferred Practice Pattern® guidelines should be clinically relevant and specific enough to provide useful information to practitioners. Where evidence exists to support a recommendation for care, the recommendation should be given an explicit rating that shows the strength of evidence. To accomplish these aims, methods from the Scottish Intercollegiate Guideline Network¹ (SIGN) and the Grading of Recommendations Assessment, Development and Evaluation² (GRADE) group are used. GRADE is a systematic approach to grading the strength of the total body of evidence that is available to support recommendations on a specific clinical management issue. Organizations that have adopted GRADE include SIGN, the World Health Organization, the Agency for Healthcare Research and Policy, and the American College of Physicians.³

- ◆ All studies used to form a recommendation for care are graded for strength of evidence individually, and that grade is listed with the study citation.
- ◆ To rate individual studies, a scale based on SIGN¹ is used. The definitions and levels of evidence to rate individual studies are as follows:

I++	High-quality meta-analyses, systematic reviews of randomized controlled trials (RCTs), or RCTs with a very low risk of bias
I+	Well-conducted meta-analyses, systematic reviews of RCTs, or RCTs with a low risk of bias
I-	Meta-analyses, systematic reviews of RCTs, or RCTs with a high risk of bias
II++	High-quality systematic reviews of case-control or cohort studies High-quality case-control or cohort studies with a very low risk of confounding or bias and a high probability that the relationship is causal
II+	Well-conducted case-control or cohort studies with a low risk of confounding or bias and a moderate probability that the relationship is causal
II-	Case-control or cohort studies with a high risk of confounding or bias and a significant risk that the relationship is not causal
III	Nonanalytic studies (e.g., case reports, case series)

- ◆ Recommendations for care are formed based on the body of the evidence. The body of evidence quality ratings are defined by GRADE² as follows:

Good quality	Further research is very unlikely to change our confidence in the estimate of effect
Moderate quality	Further research is likely to have an important impact on our confidence in the estimate of effect and may change the estimate
Insufficient quality	Further research is very likely to have an important impact on our confidence in the estimate of effect and is likely to change the estimate Any estimate of effect is very uncertain

- ◆ Key recommendations for care are defined by GRADE² as follows:

Strong recommendation	Used when the desirable effects of an intervention clearly outweigh the undesirable effects or clearly do not
Discretionary recommendation	Used when the trade-offs are less certain—either because of low-quality evidence or because evidence suggests that desirable and undesirable effects are closely balanced

- ◆ The Highlighted Findings and Recommendations for Care section lists points determined by the PPP Panel to be of particular importance to vision and quality of life outcomes.
- ◆ All recommendations for care in this PPP were rated using the system described above. Ratings are embedded throughout the PPP main text in italics.
- ◆ Literature searches to update the PPP were undertaken in June 2014 in the PubMed and Cochrane databases. Complete details of the literature searches are available in Appendix 4.



HIGHLIGHTED FINDINGS AND RECOMMENDATIONS FOR CARE

Understanding the current disease definition is important in the management of primary angle closure (PAC). Modern classification includes:

- ◆ Primary angle-closure suspect (≥ 180 degrees iridotrabeular contact [ITC], normal intraocular pressure [IOP], and no optic nerve damage)
- ◆ Primary angle closure (≥ 180 degrees ITC with peripheral anterior synechiae [PAS] or elevated IOP, but no optic neuropathy)
- ◆ Primary angle-closure glaucoma (≥ 180 degrees ITC with PAS, elevated IOP, and optic neuropathy)
- ◆ Acute angle-closure crisis (AACC; occluded angle with symptomatic high IOP)
- ◆ Plateau iris configuration (any ITC persisting after a patent laser peripheral iridotomy [LPI]) or syndrome (any ITC persisting after a patent LPI with pressure elevation after dilation)

The management of other secondary forms of angle closure (e.g., iris bombé) is not discussed in this PPP.

Common risk factors for PAC include Asian descent; hyperopia; older age; female gender; short axial length; and the size, shape, or position of the crystalline lens.

The clinical signs and symptoms of AACC include pressure-induced corneal edema (experienced as blurred vision and occasionally as multicolored haloes around lights), a mid-dilated pupil, vascular (i.e., conjunctival and episcleral) congestion, eye pain, headache, nausea, and/or vomiting.

Dark-room dynamic gonioscopy (as described in the subsection Gonioscopy in the Diagnosis section) should be performed to diagnose angle-closure disease and to verify improvement in angle configuration following treatment.

Patients experiencing AACC should receive aqueous suppressants to lower the IOP acutely and laser iridotomy or iridectomy. After addressing the episode of AACC, it is important to perform LPI in the fellow eye when indicated.



INTRODUCTION

DISEASE DEFINITION

Primary angle closure is appositional or synechial closure of the anterior chamber angle. Experts now recognize multiple mechanisms for PAC. Pupillary block is a key element in the pathogenesis of most instances of PAC.⁴⁻⁶ The pressure in the posterior chamber is higher than in the anterior chamber due to blockage of aqueous humor flow from the posterior chamber at the pupil, causing an anterior bowing of the iris that crowds the angle in predisposed eyes. Additional mechanisms that contribute to PAC include the relative position and thickness of the ciliary body, the location of the iris insertion into the ciliary body, and the volume of the iris. Certain anatomical features can increase this pressure disparity between the two chambers (e.g., pupil dilation and the crystalline lens size, shape, position, and thickening with age), which then results in iris apposition to the anterior chamber angle structures. In a minority of cases, this can happen acutely, resulting in acute angle closure.

Prolonged or repeated contact of the peripheral iris with the trabecular meshwork may lead to functional damage of the trabecular meshwork and the development of PAS. Angle closure may or may not be associated with elevated IOP or glaucomatous optic neuropathy, and it may occur in either an acute or chronic form. Secondary forms of angle closure can also occur (e.g., iridocorneal endothelial syndrome, inflammation, or neovascularization). This PPP focuses on PAC.

DISEASE CLASSIFICATION AND CLINICAL FINDINGS CHARACTERISTIC OF ANGLE CLOSURE

Primary angle closure is generally bilateral, although 90% of acute attacks are unilateral.^{7,8} Patients with angle closure and those at risk may be categorized as follows (see Table 1):

TABLE 1 CLINICAL FINDINGS THAT DEFINE PATIENTS SEEN WITH ANGLE-CLOSURE DISEASE

	Primary Angle-Closure Suspect	Primary Angle Closure	Primary Angle-Closure Glaucoma
≥180 degrees ITC	Present	Present	Present
Elevated IOP or PAS	Absent	Present	Present
Optic nerve damage	Absent	Absent	Present

IOP = intraocular pressure; ITC = iridotrabecular contact; PAS = peripheral anterior synechiae

Primary Angle-Closure Suspect

Iridotrabecular contact, as observed on gonioscopy without compression, is defined as the iris appearing to touch the anterior chamber angle at the posterior pigmented trabecular meshwork or more anterior structures. The extent of ITC required to diagnose an eye as having angle closure has been the subject of debate. Consensus suggests that a person with 180 degrees or more of ITC on dark-room gonioscopy is at risk of angle-closure glaucoma or an AACC.^{9,10} A person with this amount or more of ITC, no PAS, and normal IOP is considered a primary angle-closure suspect (PACS).⁹ Only one study (carried out in south India) has reported on the natural history of this condition. About one in four in this population developed elevation in IOP or PAS over 5 years.^{11,12} Further longitudinal studies in diverse ethnorracial populations are needed.

Primary Angle Closure and Primary Angle-Closure Glaucoma

Any eye that has at least 180 degrees of ITC and an elevated IOP or PAS with no secondary cause for the PAS is classified as having PAC. The presence of high IOP and/or PAS suggests that ITC noted during gonioscopy may be causing permanent histopathologic changes to the eye.¹³ When glaucomatous optic neuropathy is present (as defined in the Primary Open-Angle Glaucoma PPP¹⁴), the eye has progressed from PAC to primary angle-closure glaucoma (PACG).

Acute Angle-Closure Crisis

If the anterior chamber angle is obstructed suddenly, the IOP can rise rapidly to high levels. The characteristic clinical signs and symptoms include pressure-induced corneal edema (experienced as blurred vision and occasionally as multicolored haloes around lights), a mid-dilated pupil, vascular (i.e., conjunctival and episcleral) congestion, eye pain, headache, nausea, and/or vomiting. This condition is considered an AACC. Acute angle-closure crisis may be self-limited and resolve spontaneously or it may recur. Untreated, this entity may cause permanent vision loss or blindness. The fellow eye is also at high risk of AACC.

Plateau Iris Configuration and Syndrome

Plateau iris configuration refers to eyes that continue to have ITC after iridotomy, with a gonioscopic appearance of the peripheral iris closely apposed to the angle despite a deep central anterior chamber. Nearly one-third of PAC eyes treated with iridotomy have an angle that retains significant ITC.¹⁵⁻¹⁹ On pupil dilation, eyes with plateau iris configuration do not have a significant increase in IOP. No longitudinal study has shown that these eyes have a long-term risk to develop PACG that is higher than the eyes whose angles widen more after iridotomy. Rarely, eyes with plateau iris configuration do have recurrent high IOP spikes after iridotomy; these eyes are classified as having plateau iris syndrome and require more extensive treatments.

PATIENT POPULATION

The patient population includes individuals of all ages, most of whom are adults over 50 years of age who have risk factors that include abnormally high transpupillary resistance to aqueous humor movement, most often in association with pupillary block.

CLINICAL OBJECTIVES

- ◆ Identify patients who currently have or are at risk of developing PACG or AACC by using gonioscopy
- ◆ Successfully manage AACC
- ◆ Prevent or reverse angle closure by using laser iridotomy and/or iridoplasty when indicated, and by using incisional iridectomy when necessary to alleviate pupillary block
- ◆ Confirm by repeat gonioscopy that the angle is open after intervention. If not, consider incisional surgery when laser therapy does not alleviate pupillary block.
- ◆ Identify and manage patients with chronic IOP elevation that persists after iridotomy or iridoplasty
- ◆ Evaluate the fellow eye for evidence of angle closure or an anatomically narrow angle in AACC, and consider performing a prophylactic iridotomy when indicated
- ◆ Educate the patient and family members about the characteristics of the disease and involve them in the patient's management. Also, communicate to family members that they themselves may be at risk of angle closure and should be evaluated.



BACKGROUND

PREVALENCE

There are considerable differences in the prevalence of angle closure among ethnoracial groups. The highest rates are reported in Inuit,²⁰⁻²² Chinese,²³⁻²⁷ and other Asian²⁸⁻³⁶ populations; lower rates are reported in populations of African and African-derived origin³⁷⁻³⁹ and European and European-derived origin⁴⁰⁻⁴⁸ (see Table 2). Primary angle-closure glaucoma may account for nearly as many cases of glaucoma as open-angle glaucoma in some Asian populations.^{28,49,50} Worldwide, 0.7% of people over 40 years of age are estimated to have angle-closure glaucoma⁵⁰; in 2013, this represented 20.2 million people, with most (15.5 million) in Asia.⁵¹ In China, PACG is estimated to cause unilateral blindness (visual acuity <20/200 or visual field $\leq 10^\circ$) in 1.5 million individuals and bilateral blindness in another 1.5 million.⁴⁹

TABLE 2 PREVALENCE OF ANGLE CLOSURE

Population	Location	Study N	Reported Prevalence (%)
Inuit	Alaskan Inuit ²⁰	1673	3.8 (age >40)
	Alaskan Inuit ²¹	1686	2.65 (age >40)
	East Greenlandic Inuit ²²	79	2.5 (age ≥ 40)
Chinese	Taiwan ²³	562	3.0 (age ≥ 40)
	Guangzhou ²⁴	1504	1.5 (age ≥ 50)
	Beijing ²⁶	4451	1.2 (age ≥ 40)
	Singapore ²⁷	1232	1.1 (age 40–79)
Other Asian	Burma ²⁸	2076	2.5 (age ≥ 40)
	South Africa* ²⁹	987	2.30 (age ≥ 40)
	Mongolia ²⁵	942	1.4 (age ≥ 40)
	Thailand ³¹	790	0.9 (age ≥ 50)
	Southern India ³²	3934	0.87 (age ≥ 40)
	Southern India ³³	5150	0.5 (age ≥ 40)
	Bangladesh ³⁴	2347	0.4 (age ≥ 40)
	Japan ³⁵	8126	0.34 (age ≥ 40)
	Japan ³⁶	3021	0.6 (age ≥ 40)
Hispanic	Arizona, U.S. ⁵²	4774	0.10 (age >40)
African and African-derived	Baltimore, U.S. ³⁷	5308	0.6 (age ≥ 40)
	Tanzania ³⁸	3268	0.58 (age ≥ 40)
	Temba, South Africa ³⁹	839	0.50 (age ≥ 40)
European and European-derived	Italy ⁴⁰	4297	0.60 (age >40)
	Blue Mountains, Australia ⁴¹	3654	0.27 (age ≥ 49)
	Bedford, U.K. ⁴²	5941	0.17 (age >40)
	Ireland ⁴³	2186	0.09 (age ≥ 50)
	Wales, U.K. ⁴⁴	4231	0.09 (age ≥ 40 –75)
	Melbourne, Australia ⁴⁵	3271	0.06 (age ≥ 40)
	Beaver Dam, U.S. ⁴⁶	4926	0.04 (age ≥ 43)
	Rotterdam ⁴⁷	3062	0 (age ≥ 55)
	Sweden ⁴⁸	1963	0 (age 55–69)

NOTE: The studies reporting prevalence used different definitions of disease; therefore, these rates are not directly comparable.

* Population in study is of mixed-race ancestry, mainly from Southeast Asia, but there was some African and white admixture.

RISK FACTORS

The following demographic and ocular factors have been implicated as risk factors for the presence of PAC.

Demographic Characteristics

- ◆ Family history of angle closure^{53,54}
- ◆ Older age^{7,25,48}
- ◆ Female gender^{7,55}
- ◆ Chinese, Vietnamese, Pakistani,⁵⁶ or Inuit descent^{22,25,57-59}

Ocular Features

- ◆ Hyperopia⁶⁰⁻⁶²
- ◆ Shallow peripheral anterior chamber depth^{8,60,62-68}
- ◆ Shallow central anterior chamber depth^{62,69-73}
- ◆ Steep corneal curvature⁷⁴
- ◆ Thick crystalline lens^{62,75}
- ◆ Short axial length^{62,75,76}
- ◆ Ciliary body configuration, as in plateau iris

NATURAL HISTORY

If patients with unilateral AACC and high IOP do not receive treatment, glaucomatous optic neuropathy can occur rapidly.⁷⁷ Untreated fellow phakic eyes are at increased risk for developing acute angle closure.^{78,79} Following AACC, the retinal nerve fiber layer (RNFL) thickness increases in the first few days, returns to an average thickness at approximately 1 month, and develops decreased thickness at 3 months.⁸⁰ This occurs from axonal swelling, resolution of axonal swelling, and eventual axonal atrophy.⁷⁷ In one study, 18% of eyes were blind (10% from glaucoma), 48% of eyes developed glaucomatous optic neuropathy, and 58% of eyes had visual acuity worse than 20/40, in the 4 to 10 years following an AACC.⁸¹ Thus, visual morbidity from AACC is significant. The natural history in untreated patients with AACC and PACG is to develop progressive vision loss that may result in bilateral blindness.



CARE PROCESS

PATIENT OUTCOME CRITERIA

- ◆ Preservation of visual function
- ◆ Maintenance of quality of life
- ◆ Reduction of the risk of AACC

DIAGNOSIS

Patients may or may not have symptoms of angle closure. Primary angle-closure suspect is a diagnosis based on the presence of ITC on gonioscopy only, without elevated IOP or PAS and no optic nerve damage. Primary angle closure is based on a combination of the presence of ITC on gonioscopy with either elevated IOP or PAS, but no optic neuropathy.⁹

Patients may be asymptomatic when presenting for routine eye care, or they may present with sudden onset of symptoms and signs typical of AACC (such as pain, redness, congestion, decreased vision, corneal edema, very high IOP). The initial history and ophthalmic examination includes the

components of the comprehensive adult medical eye evaluation,⁸² with special attention to those factors that specifically bear on primary and secondary causes of angle closure (see below). In 2000, Medicare began providing a benefit for glaucoma screening for individuals with the following risk factors: a family history of glaucoma, a history of diabetes, African American race and age 50 or older, or Latino ethnicity and age 65 or older.⁸³

History

The patient should be asked about symptoms that may suggest previous episodes of intermittent angle closure (e.g., blurred vision, halos around lights, eye pain, headache, eye redness, symptoms following stress⁸⁴ or dilated eye examination^{55,85}). (*good quality, strong recommendation*) Review of the patient's family history may identify a relative with acute angle-closure glaucoma.^{53,54,86-88} Specific questioning should address the use of oral medications that may cause ciliary body edema (e.g., sulfonamides,⁸⁹ topiramate⁹⁰ [e.g., Topamax; Ortho-McNeil Neurologics, Titusville, NJ]) and topical, inhaled, or oral drugs with adrenergic or anticholinergic effects (e.g., ipratropium bromide and salbutamol-containing inhalers, phenothiazines,⁹¹ or other drugs with anticholinergic activity) that may induce angle narrowing and potentially precipitate an angle-closure attack.⁸⁵ (*good quality, strong recommendation*)

Physical Examination

Components of the physical examination that are particularly relevant for the diagnosis and management of angle closure and AACC follow.

Refractive status

Hyperopic eyes, especially in older phakic patients, have narrower anterior chamber angles⁶⁰ and are at increased risk of PAC.⁶¹ Assessment of actual refractive status by retinoscopy or manifest refraction in the AACC eye may be postponed until a subsequent visit. It is appropriate to determine the presence of hyperopia by measuring the eyeglass power or refracting the fellow eye.

Pupil

- ◆ Size and shape (may be mid-dilated, asymmetric, or oval in the involved eye during or following an AACC)
- ◆ Reactivity (may be poor during an AACC or nonreactive following an AACC)
- ◆ Relative afferent pupillary defect (may be present with asymmetric optic nerve damage or be due to elevated IOP)

Slit-lamp biomicroscopy

- ◆ Conjunctival hyperemia (in acute cases)
- ◆ Central and peripheral anterior chamber depth narrowing^{92,93}
- ◆ Anterior chamber inflammation suggestive of a recent or current attack
- ◆ Corneal swelling. (Microcystic edema and stromal edema are common in acute cases.)
- ◆ Iris abnormalities, including diffuse or focal atrophy, posterior synechiae, abnormal pupillary function, irregular pupil shape, and a mid-dilated pupil (suggestive of a recent or current attack)
- ◆ Lens changes, including cataract and glaukomflecken (patchy, localized, anterior subcapsular lens opacities) (see Figures 1 and 2)
- ◆ Corneal endothelial cell loss⁹⁴⁻⁹⁷

**Primary Angle Closure PPP:
Diagnosis**

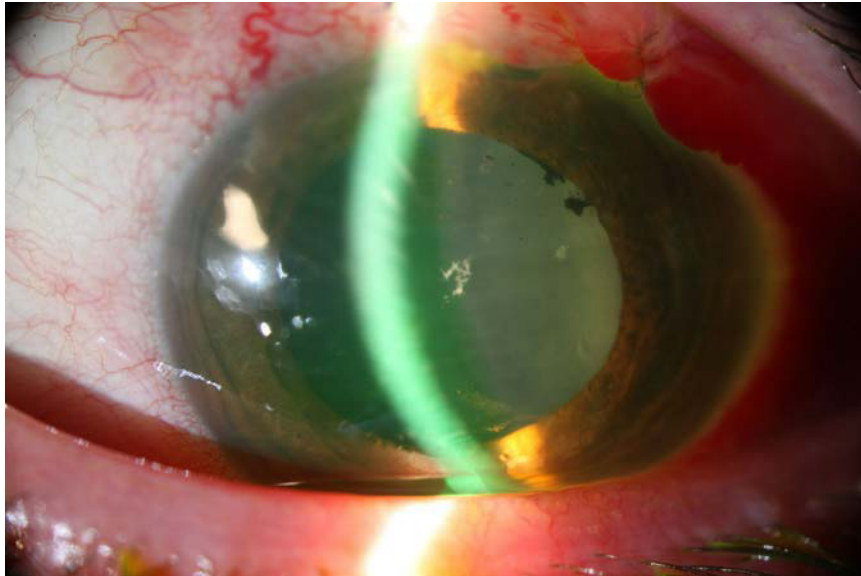


FIGURE 1. Glaukomflecken on the anterior lens surface. (Courtesy of Leon W. Herndon, Jr., MD)

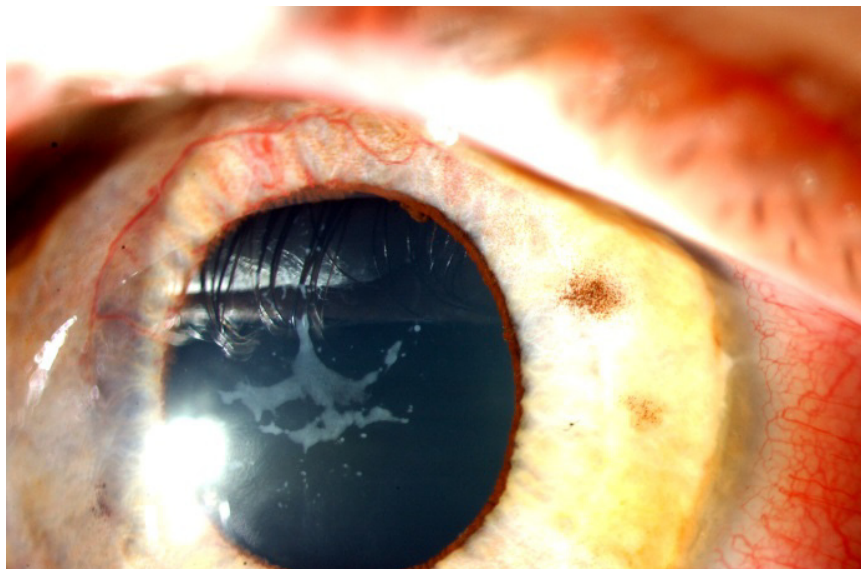

FIGURE 2. Glaukomflecken in a very young patient following a prolonged episode of acute angle closure. The opacities gradually resolved over many months after control of the intraocular pressure by immediate laser iridoplasty and subsequent laser iridotomy. (Courtesy of Bruce E. Prum, Jr., MD)

Determination of Intraocular Pressure

Intraocular pressure is measured in each eye, preferably using a contact applanation method (typically Goldmann tonometry) before gonioscopy. Measuring central corneal thickness should be postponed until resolution of an AACC.⁹⁸

Gonioscopy

Gonioscopy of both eyes should be performed on all patients in whom angle closure is suspected to evaluate the angle anatomy, presence of ITC and/or PAS, and plateau iris configuration.⁹⁹ Compression (indentation) gonioscopy with a four-mirror or similar lens is particularly helpful to determine if visible appositional closure is actually permanent synechial closure and, if so, the extent of such PAS. Gonioscopy should be performed in a dark room with a bright, short (approximately 1 mm in length) beam that does not pass through the pupil to avoid inducing pupillary constriction, which can widen the angle.¹⁰⁰ A useful technique for examining the angle in an eye with a narrow anterior chamber is to have the patient look towards the mirror of the gonioprism into which the examiner is looking. The gonioscopy lens may also be used to examine the optic disc through the central portion of the lens.

Gonioscopic visualization of the angle may be impaired secondary to corneal edema in the setting of acute angle-closure glaucoma. Topical glycerin may be used to clear the cornea to obtain a better view. (See www.gonioscopy.org and Selected Reference Texts section for discussion of the techniques of gonioscopy.)

Anterior segment imaging

Anterior segment imaging should be considered when angle anatomy is difficult to assess on gonioscopy. There is good evidence demonstrating general agreement between findings on gonioscopy and anterior segment imaging, including ultrasound biomicroscopy and anterior segment optical coherence tomography (AS-OCT).¹⁰¹⁻¹¹¹ However, AS-OCT is limited to evaluating the iridocorneal angle. Scheimpflug imaging (typically used for corneal tomography) can be used to image the anterior segment structures. These technologies may prove useful in evaluating secondary causes of angle closure (see Differential Diagnosis section) and elucidating plateau iris (see Figures 3 to 10).

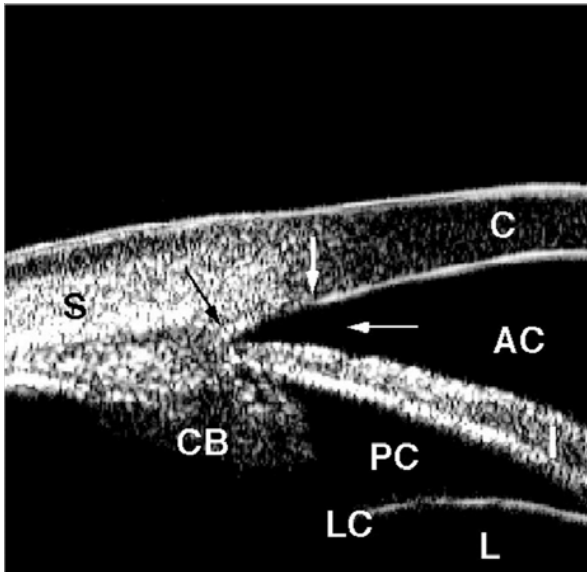


FIGURE 3. Normal-angle anatomy by ultrasound biomicroscopy.

AC = anterior chamber; C = cornea; CB = ciliary body with ciliary processes at tip; I = iris; L = lens; LC = lens capsule; PC = posterior chamber; S = sclera; black arrow = scleral spur; thick white arrow = Schwalbe's line; thin white arrow = angle recess or approach

(Courtesy of Pat-Michael Palmiero, MD. Adapted with permission from the American Academy of Ophthalmology Knowledge Base Glaucoma Panel. Practicing Ophthalmologists Learning System 2014–2016. Glaucoma review outline. Diagnostic tests: ultrasound biomicroscopy.)

**Primary Angle Closure PPP:
Diagnosis**

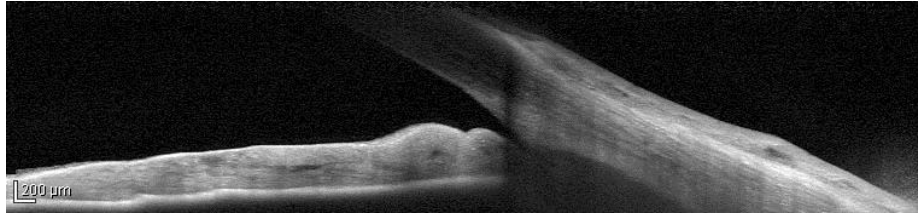


FIGURE 4. Anterior segment optical coherence tomography image showing a narrow angle prelaser peripheral iridotomy. (Courtesy of Michele C. Lim, MD)

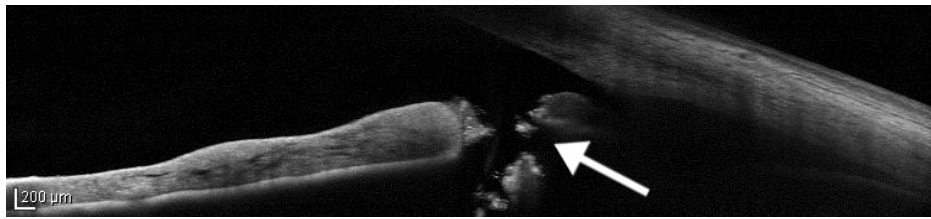


FIGURE 5. Anterior segment optical coherence tomography image showing a narrow-angle postlaser iridotomy. Arrow indicates iridotomy. (Courtesy of Michele C. Lim, MD)

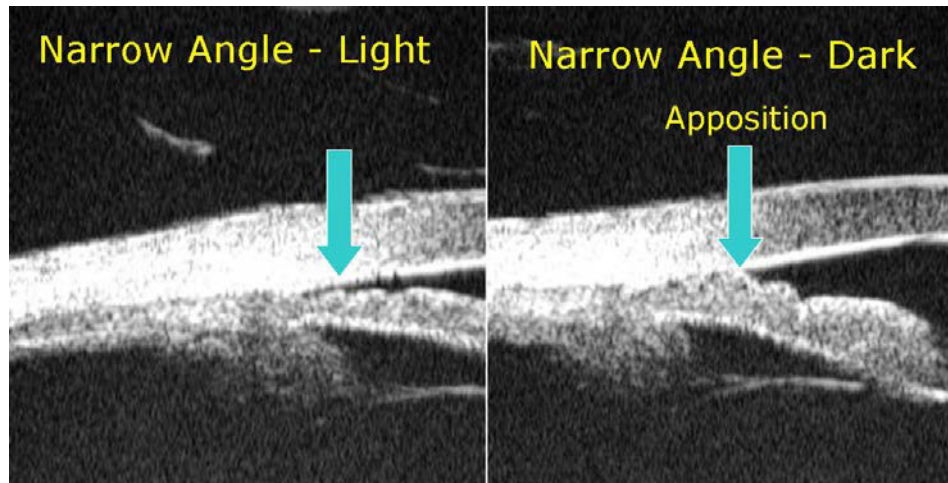


FIGURE 6. Comparative ultrasound biomicroscopy images of a narrow, occludable angle seen to be barely open in the light (left) and appositionally closed in the dark (right), denoted by arrow.

(Courtesy of Pat-Michael Palmiero, MD. Adapted with permission from the American Academy of Ophthalmology Knowledge Base Glaucoma Panel. Practicing Ophthalmologists Learning System 2014–2016. Glaucoma review outline. Diagnostic tests: ultrasound biomicroscopy.)

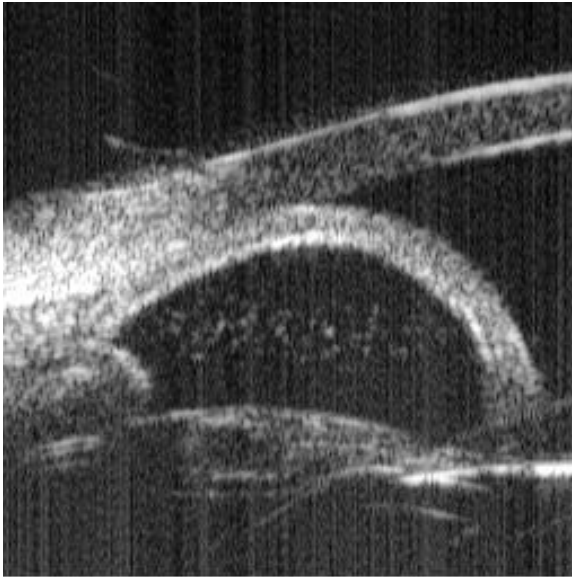


FIGURE 7. Iris bombé and acute angle closure as seen on ultrasound biomicroscopy.

(Courtesy of Pat-Michael Palmiero, MD. Adapted with permission from the American Academy of Ophthalmology Knowledge Base Glaucoma Panel. Practicing Ophthalmologists Learning System 2014–2016. Glaucoma review outline. Diagnostic tests: ultrasound biomicroscopy.)

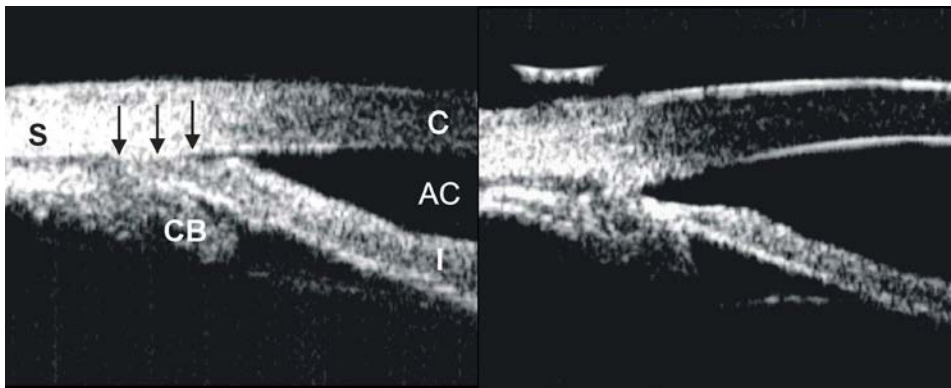


FIGURE 8. Plateau iris syndrome before (left) and after (right) laser peripheral iridoplasty, with opening of the angle recess and iris-trabecular meshwork apposition (black arrows) following iridoplasty, which results from the thermal laser energy absorbed by the iris tissue, leading to atrophy and thinning of the iris periphery (seen in the photo on the right). This thinning leads to elimination of angle closure and intraocular pressure elevation, with dilation seen after iridoplasty.

AC = anterior chamber; C = cornea; CB = ciliary body with ciliary processes; I = iris; S = sclera

(Courtesy of Pat-Michael Palmiero, MD. Adapted with permission from the American Academy of Ophthalmology Knowledge Base Glaucoma Panel. Practicing Ophthalmologists Learning System 2014–2016. Glaucoma review outline. Diagnostic tests: ultrasound biomicroscopy.)

Primary Angle Closure PPP: Diagnosis

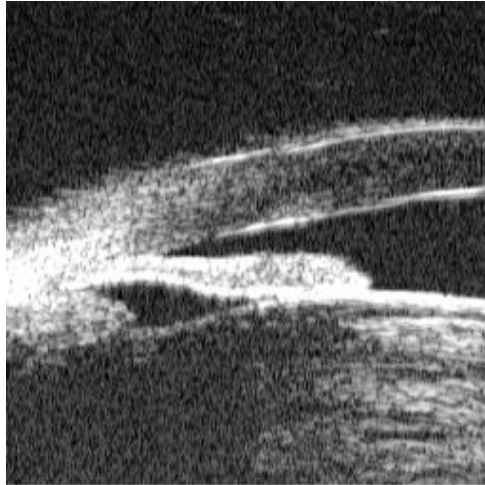


FIGURE 9. Angle closure due to a large, intumescent lens, seen on ultrasound biomicroscopy.

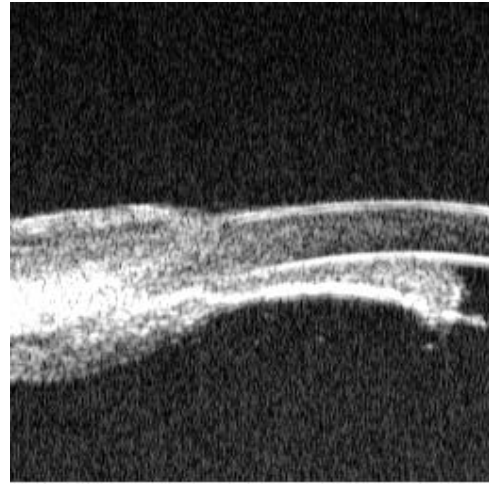


FIGURE 10. Angle closure with complete flattening of the iris against the corneal endothelium and loss of the anterior chamber due to aqueous misdirection/ malignant glaucoma, seen on ultrasound biomicroscopy.

(Courtesy of Pat-Michael Palmiero, MD. Adapted with permission from the American Academy of Ophthalmology Knowledge Base Glaucoma Panel. Practicing Ophthalmologists Learning System 2014–2016. Glaucoma review outline. Diagnostic tests: ultrasound biomicroscopy.)

Provocative testing

Careful gonioscopic examination and synthesis of the clinical findings have largely replaced the use of provocative tests to make therapeutic decisions for patients at risk for PAC.

Other components of the initial evaluation

Although a dilated examination may not be advisable for patients with ITC, an attempt should be made to optimally evaluate the fundus and optic nerve head clinically by using the direct ophthalmoscope or the slit-lamp biomicroscope with an indirect lens (e.g., 78-diopter or 90-diopter lens), or by imaging the retina and optic nerve with photography using a nonmydriatic camera through an undilated pupil. In many cases, it may also be possible to obtain OCT imaging of the optic nerves through an undilated pupil to ascertain and document the status of the optic nerve. For patients with suspected occludable angles, pupil dilation should be done with caution. As appropriate, these patients should be warned about signs and symptoms until an iridotomy has been performed, since dilation can precipitate AACCs.⁵⁵ (*good quality, strong recommendation*) However, if dilation is deemed essential (e.g., for suspected retinal pathology), cautious dilation with low-strength tropicamide can be performed. If angle closure is precipitated by dilation in the clinic, it can be successfully managed during the encounter. Once an iridotomy has been performed, a dilated examination of the retina and optic nerve can be done for more complete documentation of the ONH and RNFL. (See Primary Open-Angle Glaucoma PPP for a detailed description of the evaluation.¹⁴) Dark-room gonioscopy and IOP measurements should be performed pre- and post-dilation to ensure a non-occludable angle following the LPI. (*good quality, strong recommendation*)

Differential Diagnosis

Because PACS and PAC tend to be bilateral, the observation of a wide open angle in the fellow eye suggests a diagnosis other than PAC. Other entities that cause secondary anterior chamber angle closure and that may be unilateral or bilateral can be classified as follows:

- ◆ Pulling mechanism
 - ◆ Secondary angle closure due to iris membranes:
 - Neovascularization of the iris
 - Epithelial downgrowth or fibrous ingrowth
 - Descemetization of the anterior chamber angle, as in iridocorneal endothelial syndrome
 - Contracture of inflammatory precipitates
 - Axenfeld-Rieger syndrome
 - PAS following anterior segment surgery
- ◆ Pushing mechanism
 - ◆ Secondary pupillary block due to the following:
 - Uveitis with secondary posterior synechiae leading to iris bombé
 - Lens-related disorders (e.g., ectopia lentis or malpositioned intraocular lenses [IOLs])
 - ◆ Retinal conditions leading to the forward shift of the lens-iris diaphragm
 - Ciliary body edema and/or uveal effusion secondary to:
 - Central retinal vein occlusion
 - Panretinal photocoagulation
 - Placement of a scleral buckle
 - Intraocular gas or silicone oil with forward displacement of the lens-iris diaphragm
 - Persistent fetal vasculature
 - Chronic serous choroidal detachment (effusion)
 - Hemorrhagic choroidal detachment (suprachoroidal hemorrhage)
 - Intraocular tumors (mass effect or direct angle invasion)
 - Retinopathy of prematurity
 - ◆ Aqueous misdirection (malignant glaucoma)

MANAGEMENT

Goals

The goals of managing a patient with PAC are as follows:

- ◆ Reverse or prevent the angle-closure process
- ◆ Control IOP
- ◆ Prevent damage to the optic nerve

Primary Angle-Closure Suspect

No completed clinical trials have documented the benefit of iridotomy for PACS, yet the relative safety of this procedure has allowed its wider use in the hope of preventing AACC and PACG. Observational studies suggest that the majority of patients with PACS will not develop either PAC or PACG.^{12,112} In patients with ITC and normal IOP without PAS, iridotomy may be considered to reduce the risk of developing angle closure. Alternatively, patients with ITC may be followed for development of IOP elevation, evidence of progressive narrowing, or synechial angle closure, since iridotomy can rarely be associated with bothersome postoperative glare and/or diplopia. Hastening the progression of cataract and the development of posterior synechiae are occasional consequences.

Primary Angle Closure PPP: Management

Other factors that may influence the decision to perform prophylactic laser iridotomy in PACS include the following:

- ◆ Medication is required that may provoke pupillary block
- ◆ Symptoms are present that suggest prior acute angle closure
- ◆ The patient's health status or occupation/avocation makes it difficult to access immediate ophthalmic care (e.g., the patient resides in a nursing home facility, travels frequently to developing parts of the world, works on a merchant vessel), or if the patient is poorly compliant with follow-up

Patients with PACS who have not had an iridotomy should be warned that they are at risk for AACC and that certain medicines (e.g., over-the-counter decongestants, motion-sickness medication, anticholinergic agents) could cause pupil dilation and induce AACC.⁵⁵ (*III, moderate quality, discretionary recommendation*) They should also be informed about the symptoms of AACC and instructed to notify their ophthalmologist immediately if symptoms occur.¹¹² (*III, moderate quality, strong recommendation*) Many PACS patients may develop increased IOP and require topical ocular hypotensive agents after LPI.^{113,114}

Primary Angle Closure and Primary Angle-Closure Glaucoma

Patients with PAC may have elevated IOP as a result of a chronic compromise of aqueous outflow due to appositional or synechial angle closure, or from damage to the trabecular meshwork after previous intermittent AACC. Iridotomy is indicated for eyes with PAC or PACG.^{9,115} (*I++ , good quality, strong recommendation*) This may be performed using either a thermal or neodymium yttrium-aluminum-garnet (Nd:YAG) laser.

Complications of laser iridotomy include increased IOP; laser burn to the cornea, lens, or retina; late-onset corneal edema; development of posterior synechiae; hyphema; iritis; and the development of ocular dysphotopsias. Many advocate for horizontal placement of the iridotomy to reduce the risk of dysphotopsia.¹¹⁶ This complication may result from the prismatic effect of the tear film at the eyelid margin or shutter effect of the eyelid partially covering an iridotomy that is adjacent to the eyelid margin and either not fully covered by the eyelid or not fully exposed at the 3 or 9 o'clock position.

Surgery and Postoperative Care

The ophthalmologist who performs the laser iridotomy or incisional iridectomy has the following responsibilities:

- ◆ Obtain informed consent from the patient or the patient's surrogate decision maker after discussing the risks, benefits, and expected outcomes of surgery¹¹⁷
- ◆ Ensure that the preoperative evaluation confirms the need for surgery¹¹⁷
- ◆ Use preoperative low-strength miotics to facilitate laser iridotomy or iridectomy
- ◆ Use topical ocular hypotensive agents perioperatively to prevent sudden IOP elevation, particularly for patients who have severe disease¹¹⁸
- ◆ Ensure the patency of the iridotomy by directly visualizing fluid flow of aqueous and pigment from the posterior to the anterior chamber and by visualizing the anterior lens capsule. Visualization of a red reflex alone is insufficient to confirm patency.
- ◆ Perform at least one IOP check immediately prior to surgery and within 30 minutes to 2 hours following laser surgery¹¹⁸⁻¹²⁰
- ◆ Prescribe topical corticosteroids in the postoperative period
- ◆ Ensure that the patient receives adequate postoperative care¹²¹

Follow-up evaluations in the days and weeks after surgery should include the following elements:

- ◆ Confirm the patency of the iridotomy by visualizing the anterior lens capsule
- ◆ Measure IOP
- ◆ Perform dark-room gonioscopy with compression/indentation to assess the extent of PAS, if it was not performed immediately following the iridotomy
- ◆ Dilate the pupil to decrease the risk of posterior synechiae formation
- ◆ Examine the fundus as clinically indicated

Following iridotomy for PAC, persistent or progressive elevations of IOP and complications may occur for several reasons:

- ◆ Trabecular damage or formation of PAS may have occurred during iridocorneal apposition
- ◆ If the iridotomy becomes occluded, pupillary block may recur. Reoperation is indicated.
- ◆ Factors other than pupillary block may lead to angle closure and may have gone unrecognized until after the iridotomy. These include plateau iris syndrome, phacomorphic angle closure, and secondary causes of pupillary block (see Differential Diagnosis section).
- ◆ Angle closure may have been superimposed on pre-existing open-angle glaucoma or on another cause of IOP elevation, such as exfoliation syndrome¹²²⁻¹²⁵

Additional treatment of PAC or PACG after the component of pupillary block has been alleviated by iridotomy is directed at lowering IOP to prevent or retard pressure-induced optic nerve damage and is similar to the treatment of primary open-angle glaucoma.¹⁴ Reopening the angle by laser iridoplasty or surgical lysis of synechiae (goniosynechialysis) may improve aqueous outflow, especially when it is performed within 6 to 12 months of an AACC.¹²⁶⁻¹²⁹

Additional management for elevated IOP that threatens the optic nerve is the same as for primary open-angle glaucoma (see Primary Open-Angle Glaucoma PPP¹⁴). It includes chronic topical ocular hypotensive agents, incisional surgery, trabeculectomy or tube shunt, and, rarely, laser trabeculoplasty if, in the judgment of the treating ophthalmologist, sufficiently open trabecular meshwork exists following laser iridotomy to expect a reasonable IOP reduction. In addition, a growing body of evidence indicates that cataract extraction alone may lead to substantial IOP lowering in some PACG patients and can be considered as an option for treatment.¹³⁰⁻¹⁴⁷ (*I+, good quality, discretionary recommendation*)

Acute Angle-Closure Crisis

Acute attack management

The initial treatment of AACC is aimed at lowering IOP to relieve the acute symptoms and potentially harmful high IOP. Several methods have been studied, including medical therapy alone, LPI (if the iris can be visualized and the procedure can be performed), peripheral laser iridoplasty, and paracentesis.¹⁴⁸⁻¹⁵⁰ However, most patients are treated acutely with medications, and the iridotomy is performed as soon as feasible.

Iridotomy (or iridectomy) allows aqueous to bypass the pupillary block and eliminates the pressure gradient between the posterior and anterior chambers.

In AACC, medical therapy is usually initiated first to lower the IOP to reduce pain and to clear corneal edema. Iridotomy should then be performed as soon as possible.⁹ (*III, good quality, strong recommendation*) Medical therapy includes some or all of the following, based on the patient's overall physical and medical status.¹⁵¹

- ◆ Topical beta-adrenergic antagonists¹⁵²
- ◆ Topical alpha₂-adrenergic agonists¹⁵³
- ◆ Topical, oral, or intravenous carbonic anhydrase inhibitors¹⁵²
- ◆ Topical miotics^{152,154}
- ◆ Oral or intravenous hyperosmotic agents

Agents that suppress aqueous humor formation (beta-adrenergic antagonists, carbonic anhydrase inhibitors) may be ineffective initially, because they may have decreased ability to reduce aqueous formation if the ciliary body is ischemic. As the configuration of the iris becomes less bowed with a small pupil, treatment using miotics may open the angle; however, miotic therapy is frequently ineffective when the IOP is markedly elevated because of pressure-induced ischemia of the pupillary sphincter. Miotic treatment may be ineffective in cases of secondary pupillary block due to intraocular gas, oil, or vitreous, or if the IOL or crystalline lens is blocking the pupil. In these cases, mydriatics may be more effective. Systemic hyperosmotic agents may need to be used to achieve a rapid decrease in IOP in the setting of AACC. Corneal indentation performed with a four-mirror gonioscopic lens, cotton-tipped applicator, or tip of a muscle hook may help break pupillary block.¹⁵⁵

Laser iridotomy is the preferred surgical treatment because it has a favorable risk-benefit ratio.^{15,156,157} (*II+, moderate quality, strong recommendation*) Iridotomy relieves pupillary block and can prevent or retard the formation of PAS. Iridotomy can also result in significant angle widening and iris-profile flattening.¹⁵⁸⁻¹⁶⁰ Timely treatment may prevent damage to the optic nerve, trabecular meshwork, iris, lens, and cornea. If an iridotomy cannot be performed due to corneal edema, the cornea may sometimes be cleared with topical hyperosmotic agents or anterior chamber paracentesis.¹⁶¹ Once the attack is broken, it is usually possible to perform a definitive laser iridotomy immediately or soon afterward.¹⁶²⁻¹⁶⁹

When laser iridotomy is not possible or if the AACC cannot be medically broken, LPI (even with a cloudy cornea),¹⁶⁸ paracentesis,^{150,170} and incisional iridectomy remain effective alternatives. (*II+, moderate quality, discretionary recommendation*) When incisional iridectomy is required and extensive synechial closure is recognized or suspected, simultaneous primary filtering surgery may be considered. Concurrent glaucomatous cupping of the optic disc often indicates a prolonged chronic course before the onset of acute symptoms, and filtering surgery can be considered, especially if the presence of considerable PAS is confirmed on gonioscopy. Filtering surgery in eyes with unbroken acute angle closure has a high risk of developing a flat anterior chamber and aqueous misdirection postoperatively.^{171,172}

Lens extraction for angle closure

Numerous studies document that lens extraction significantly widens the anterior chamber angle in eyes that have narrow, occludable angles and in angle-closure glaucoma.¹³⁰⁻¹³⁴ In prospective and retrospective studies, cataract surgery also has been shown to lower postoperative medication requirements and decrease complications compared with surgical iridectomy or trabeculectomy for angle-closure glaucoma^{137-146,173} and AACC.¹⁴⁷ Although there is evidence that lens extraction with or without goniosynechialysis^{126,174-176} can substantially lower IOP, it has been documented that cataract extraction alone does not result in as low an IOP as trabeculectomy and cataract surgery.¹⁷⁷ The risks and benefits of different procedures in eyes with angle closure should be considered when determining the most appropriate surgery.

A randomized trial on cataract surgery soon after AACC is broken compared with routine follow-up following iridotomy alone found that individuals with high IOP (>55 mmHg) were much less likely to require IOP-lowering therapy if they had early cataract extraction.¹⁴⁷ In this study, patients had phacoemulsification within 5.7 ± 3.3 (mean \pm standard deviation) days and iridotomy within 4.3 ± 2.7 (mean \pm standard deviation) days of the AACC. Early cataract surgery can be considered following AACC in patients with a high risk of developing uncontrollable IOP. However, cataract surgery in AACC eyes may have greater risk of operative complications due to the small dimensions of the anterior chamber and the tendency for choroidal expansion. Another randomized controlled trial compared the 2-year efficacy of phacoemulsification and IOL placement with LPI in the early management of AACC and coexisting cataract.¹⁷⁸ The primary outcome measure was

failure of IOP control defined as IOP between 22 and 24 mmHg on two occasions or IOP of 25 mmHg or greater on one occasion, either occurring after week 3. The 2-year cumulative survival was 61.1% and 89.5% for the LPI and phacoemulsification/IOL groups, respectively. A multinational randomized controlled prospective trial is under way to address for the first time the effectiveness of clear lens extraction with IOL implantation for the treatment of PACG (the Effectiveness in Angle-closure Glaucoma of Lens Extraction [EAGLE] Study).¹⁷⁹

Fellow-eye management

The fellow eye of a patient with AACC should be evaluated, because it is at high risk for a similar event. The fellow eye should be scheduled for a prophylactic laser iridotomy promptly if the chamber angle is anatomically narrow, since approximately half of fellow eyes of acute angle-closure patients can develop AACCs within 5 years.^{78,79,112,115,180-182} (*II++*, *good quality, strong recommendation*) These attacks can occur within days of presentation and, therefore, an ophthalmologist should consider LPI in the fellow eye as soon as possible. (*III*, *moderate quality, strong recommendation*) Chronic miotic therapy is not an appropriate alternative, either for prophylaxis of the fellow eye or for treatment of established angle closure, and it is not a substitute for iridotomy. About 40% of fellow eyes treated with miotics can develop an AACC within 5 years, and many eyes with angle closure can develop progressive formation of synechial angle closure with miotic use.^{79,182} Prophylactic LPIs are effective in preventing acute angle closure in the fellow eye.¹⁸¹

Plateau Iris Configuration and Syndrome

The success of prophylactic LPI after laser iridotomy to prevent PACG and AACC in eyes with plateau iris has been reported in a case series.¹⁸³ However, a recent Cochrane review found no randomized controlled trials to provide evidence to support the use of this procedure in these eyes.¹⁸⁴ Given the lack of convincing evidence in the literature for prophylactic use of iridoplasty in these patients, and since iridoplasty can be painful for the patient and may cause inflammation, the decision of whether to observe or treat these eyes is left to the judgment of the treating ophthalmologist. Eyes with recurrent high IOP after iridotomy when the pupil is dilated (plateau iris syndrome) should undergo further therapy, including iridoplasty, chronic miotic therapy, or other surgical procedures.⁹ (*II+*, *moderate quality, discretionary recommendation*)

Follow-up Evaluation

The recommendations for follow-up evaluations after iridotomy for angle closure apply to ongoing management and not to visits for other purposes. Following iridotomy, patients may have an open anterior chamber angle or an anterior chamber angle with a combination of open sectors with areas occluded by PAS. With or without glaucomatous optic neuropathy, patients with a residual open angle or a combination of open angle and some PAS should be followed at appropriate intervals to check for increasing PAS.⁹ (*III*, *insufficient quality, discretionary recommendation*) Special attention should be given to repeat gonioscopy to determine interval changes such as increased extent of PAS or development of secondary angle closure from cataract progression and increased lens thickness. Subsequent follow-up intervals depend on the clinical findings and judgment of the treating ophthalmologist.

If IOP remains elevated long term and the patient develops what has been called “chronic angle-closure glaucoma,” then ongoing medical therapy to lower IOP may become necessary. In such a situation, follow-up procedures and intervals would be dictated by the same principles outlined in the Primary Open-Angle Glaucoma PPP. As in primary open-angle glaucoma, adherence to medical therapy may be handicapped when patients run out of medication, due to inadvertent drop wastage or inability to properly instill eyedrops, before they are permitted to refill their prescription. However, according to a 2010 directive, patients with Medicare insurance may now refill their medication after they have completed at least 70% of the month, or approximately 21 days of therapy.¹⁸⁵

PROVIDER AND SETTING

The performance of certain diagnostic procedures (e.g., tonometry, perimetry, pachymetry, anterior segment imaging, optic disc imaging, and photography) may be delegated to appropriately trained and supervised personnel. However, the interpretation of results and medical and surgical management of disease require the medical training, clinical judgment, and experience of the ophthalmologist. (*good quality, strong recommendation*) Most diagnostic and therapeutic procedures can be undertaken safely on an outpatient basis. Hospitalization may be indicated for intensive treatment of an AACC so that patients can be monitored closely after surgical procedures associated with a high risk of serious short-term postoperative complications. It may also be indicated for patients who have experienced surgical complications or for patients who have special medical or social needs.

COUNSELING AND REFERRAL

If the diagnosis or management of PAC, PACS, AACC, or PACG is in question or is refractory to treatment, consultation with or referral to an ophthalmologist with special training or experience in managing these conditions may be indicated. Patients with significant visual impairment or blindness may benefit from appropriate vision rehabilitation and social services.¹⁸⁶ More information on vision rehabilitation, including materials for patients, is available at www.aao.org/smart-sight-low-vision.

SOCIOECONOMIC CONSIDERATIONS

Currently, there are over 61 million persons with glaucoma worldwide, approximately 45 million with open-angle glaucoma and another 16 million with PACG.⁵⁰ Since the prevalence of glaucoma increases considerably with age and people are living longer, it is estimated that by the year 2020, global glaucoma prevalence will reach nearly 80 million⁵⁰ and 112 million by 2040.⁵¹ Thus, the burden of disease both to the individual patient and the economic burden to society is substantial.¹⁸⁷

At the individual patient level, research has demonstrated that glaucoma can have a dramatic impact on a patient's well-being. Patients with glaucoma may struggle with daily activities such as reading, walking, and driving.¹⁸⁸ Performance of these activities deteriorates with worsening of glaucoma severity and when both eyes are affected. Studies have reported that patients with glaucoma are three times more likely to experience falls and six times more likely to be involved in motor vehicle collisions compared with controls.¹⁸⁹ Quality of life is affected for patients with all stages of glaucoma, even those with early disease.¹⁹⁰

The costs of managing a chronic disease like glaucoma can be broken down into direct medical costs, direct nonmedical costs, and indirect costs. Direct costs include costs of visits to eye care providers, ancillary testing, and medical and surgical interventions. One study estimated that nearly \$3 billion USD per year is spent on the direct medical costs of glaucoma.¹⁹¹ Direct nonmedical costs (e.g., costs for transportation to appointments and nursing home care) and indirect costs (e.g., loss of productivity of the patient or caregivers) can be more difficult to quantify but are substantial. Using California Medicare claims data and Markov modeling, one study estimated that the average direct and indirect medical costs for patients with glaucoma are \$1688 higher over a lifetime than for other patients without this condition.¹⁹²

Costs of glaucoma are impacted by disease severity and type of glaucoma. One study determined the average annual direct medical costs for patients with early glaucoma, advanced glaucoma, and end-stage glaucoma were \$623, \$1915, and \$2511, respectively.¹⁹³ Among patients with early glaucoma, most of the costs of care are for medications.¹⁹⁴ For those with advanced disease, indirect costs such as costs for home health care and rehabilitation predominate.^{195,196} A study of enrollees in Medicare using 2009 claims data compared mean payments per beneficiary for those with open-angle glaucoma versus angle-closure glaucoma. The study found the mean payment for angle-closure glaucoma beneficiaries was significantly higher (\$303 compared with \$263 USD). The higher costs in the study were driven by mean greater use of laser surgery in the angle-closure beneficiary group.¹⁹⁷

When considering the economic burden of glaucoma, it is important to appreciate that glaucoma affects a disproportionately large number of racial minorities. In fact, glaucoma is the leading cause of blindness among blacks, and studies have demonstrated greater risk of glaucoma among Latinos and Asian Americans relative to non-Hispanic whites as well. Various studies have noted disparities in utilization of eye care services among racial minorities. Studies have demonstrated that blacks are somewhat less likely to undergo examinations for glaucoma relative to whites,^{198,199} have lower rates of undergoing visual field testing relative to whites in the year before glaucoma surgery,²⁰⁰ and have lower rates of using of medical and surgical interventions for glaucoma.²⁰¹ A more recent study found that despite possessing health insurance, Latinos were significantly less likely to undergo monitoring for glaucoma relative to whites.²⁰² With the passage of the Affordable Care Act and other recent health care reforms, it will be important to ensure that racial minorities and socioeconomically disadvantaged patients have adequate access to eye care services and receive care that is in line with recommended clinical practice guidelines.



APPENDIX 1. QUALITY OF OPHTHALMIC CARE CORE CRITERIA

*Providing quality care
is the physician's foremost ethical obligation, and is
the basis of public trust in physicians.
AMA Board of Trustees, 1986*

Quality ophthalmic care is provided in a manner and with the skill that is consistent with the best interests of the patient. The discussion that follows characterizes the core elements of such care.

The ophthalmologist is first and foremost a physician. As such, the ophthalmologist demonstrates compassion and concern for the individual, and utilizes the science and art of medicine to help alleviate patient fear and suffering. The ophthalmologist strives to develop and maintain clinical skills at the highest feasible level, consistent with the needs of patients, through training and continuing education. The ophthalmologist evaluates those skills and medical knowledge in relation to the needs of the patient and responds accordingly. The ophthalmologist also ensures that needy patients receive necessary care directly or through referral to appropriate persons and facilities that will provide such care, and he or she supports activities that promote health and prevent disease and disability.

The ophthalmologist recognizes that disease places patients in a disadvantaged, dependent state. The ophthalmologist respects the dignity and integrity of his or her patients, and does not exploit their vulnerability.

Quality ophthalmic care has the following optimal attributes, among others.

- ◆ The essence of quality care is a meaningful partnership relationship between patient and physician. The ophthalmologist strives to communicate effectively with his or her patients, listening carefully to their needs and concerns. In turn, the ophthalmologist educates his or her patients about the nature and prognosis of their condition and about proper and appropriate therapeutic modalities. This is to ensure their meaningful participation (appropriate to their unique physical, intellectual, and emotional state) in decisions affecting their management and care, to improve their motivation and compliance with the agreed plan of treatment, and to help alleviate their fears and concerns.
- ◆ The ophthalmologist uses his or her best judgment in choosing and timing appropriate diagnostic and therapeutic modalities as well as the frequency of evaluation and follow-up, with due regard to the urgency and nature of the patient's condition and unique needs and desires.
- ◆ The ophthalmologist carries out only those procedures for which he or she is adequately trained, experienced, and competent, or, when necessary, is assisted by someone who is, depending on the urgency of the problem and availability and accessibility of alternative providers.
- ◆ Patients are assured access to, and continuity of, needed and appropriate ophthalmic care, which can be described as follows.
 - ◆ The ophthalmologist treats patients with due regard to timeliness, appropriateness, and his or her own ability to provide such care.
 - ◆ The operating ophthalmologist makes adequate provision for appropriate pre- and postoperative patient care.
 - ◆ When the ophthalmologist is unavailable for his or her patient, he or she provides appropriate alternate ophthalmic care, with adequate mechanisms for informing patients of the existence of such care and procedures for obtaining it.
 - ◆ The ophthalmologist refers patients to other ophthalmologists and eye care providers based on the timeliness and appropriateness of such referral, the patient's needs, the competence and qualifications of the person to whom the referral is made, and access and availability.

- ◆ The ophthalmologist seeks appropriate consultation with due regard to the nature of the ocular or other medical or surgical problem. Consultants are suggested for their skill, competence, and accessibility. They receive as complete and accurate an accounting of the problem as necessary to provide efficient and effective advice or intervention, and in turn they respond in an adequate and timely manner. The ophthalmologist maintains complete and accurate medical records.
- ◆ On appropriate request, the ophthalmologist provides a full and accurate rendering of the patient's records in his or her possession.
- ◆ The ophthalmologist reviews the results of consultations and laboratory tests in a timely and effective manner and takes appropriate actions.
- ◆ The ophthalmologist and those who assist in providing care identify themselves and their profession.
- ◆ For patients whose conditions fail to respond to treatment and for whom further treatment is unavailable, the ophthalmologist provides proper professional support, counseling, rehabilitative and social services, and referral as appropriate and accessible.
- ◆ Prior to therapeutic or invasive diagnostic procedures, the ophthalmologist becomes appropriately conversant with the patient's condition by collecting pertinent historical information and performing relevant preoperative examinations. Additionally, he or she enables the patient to reach a fully informed decision by providing an accurate and truthful explanation of the diagnosis; the nature, purpose, risks, benefits, and probability of success of the proposed treatment and of alternative treatment; and the risks and benefits of no treatment.
- ◆ The ophthalmologist adopts new technology (e.g., drugs, devices, surgical techniques) in judicious fashion, appropriate to the cost and potential benefit relative to existing alternatives and to its demonstrated safety and efficacy.
- ◆ The ophthalmologist enhances the quality of care he or she provides by periodically reviewing and assessing his or her personal performance in relation to established standards, and by revising or altering his or her practices and techniques appropriately.
- ◆ The ophthalmologist improves ophthalmic care by communicating to colleagues, through appropriate professional channels, knowledge gained through clinical research and practice. This includes alerting colleagues of instances of unusual or unexpected rates of complications and problems related to new drugs, devices, or procedures.
- ◆ The ophthalmologist provides care in suitably staffed and equipped facilities adequate to deal with potential ocular and systemic complications requiring immediate attention.
- ◆ The ophthalmologist also provides ophthalmic care in a manner that is cost effective without unacceptably compromising accepted standards of quality.

Reviewed by: Council
Approved by: Board of Trustees
October 12, 1988

2nd Printing: January 1991

3rd Printing: August 2001

4th Printing: July 2005



APPENDIX 2. INTERNATIONAL STATISTICAL CLASSIFICATION OF DISEASES AND RELATED HEALTH PROBLEMS (ICD) CODES

Primary angle closure includes the entity of primary angle-closure glaucoma and related entities with the following ICD-9 and ICD-10 classifications:

	ICD-9 CM	ICD-10 CM
Primary angle-closure glaucoma (PACG)	365.20	H40.20X-
Acute angle-closure glaucoma (AACC)	365.22	H40.211 H40.212 H40.213
Intermittent angle closure	365.21	H40.231 H40.232 H40.233
Chronic angle-closure glaucoma	365.23	H40.221- H40.222- H40.223-
Residual stage of angle-closure glaucoma	365.24	H40.241 H40.242 H40.243
Anatomical narrow angle (PACS)	365.02	H40.031 H40.032 H40.033
Plateau iris syndrome	364.82	H21.82
Primary angle closure (PAC) without glaucoma damage	365.06	H40.061 H40.062 H40.063

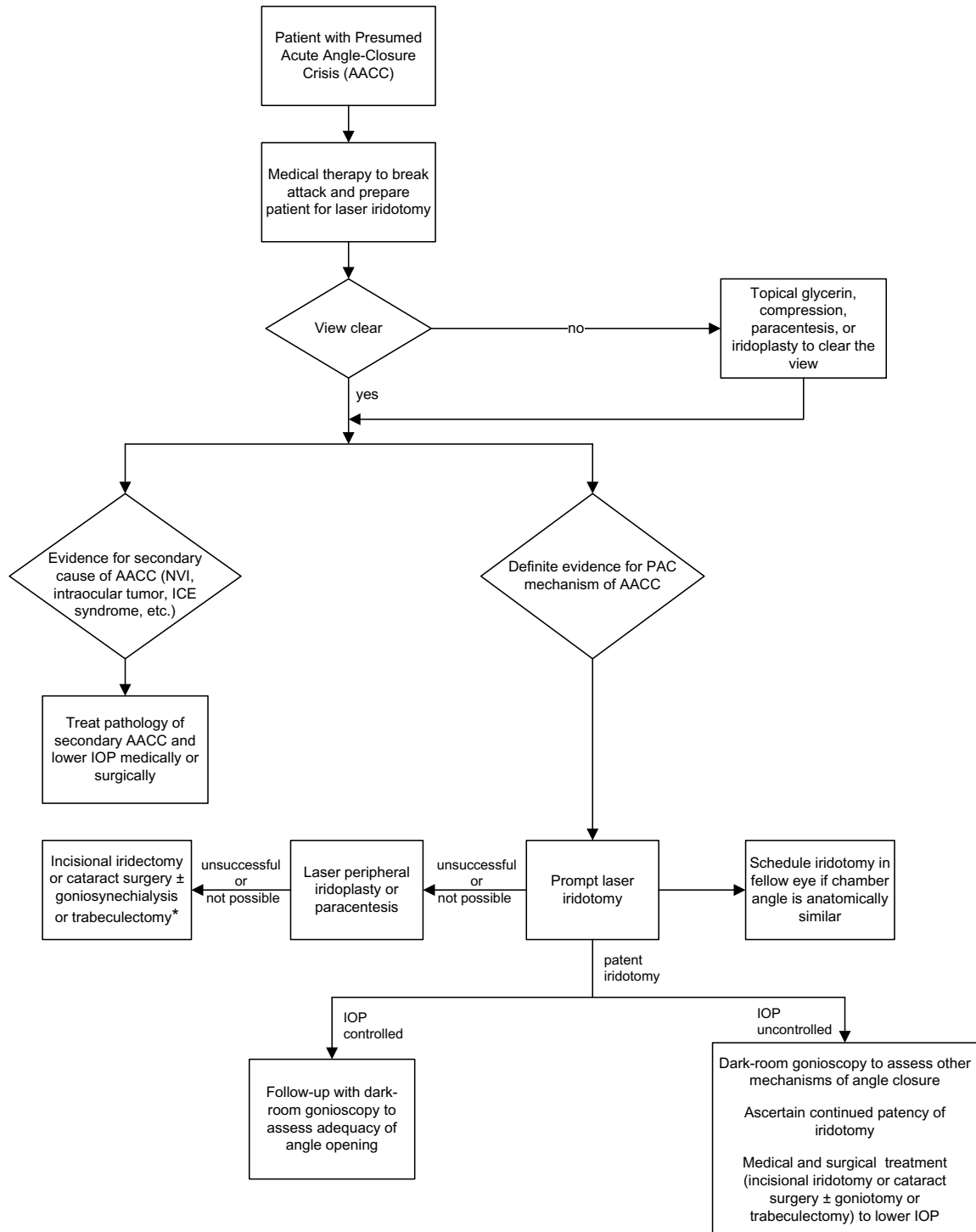
AACC = acute angle closure crisis; CM = Clinical Modification used in the United States; (-) = 0, stage unspecified; 1, mild stage; 2, moderate stage; 3, severe stage; 4, indeterminate stage; PACS = primary angle-closure suspect

Additional information for ICD-10 codes:

- Certain ICD-10 CM categories have applicable 7th characters. The applicable 7th character is required for all codes within the category, or as the notes in the Tabular List instruct. The 7th character must always be the 7th character in the data field. If a code that requires a 7th character is not 6 characters, a placeholder X must be used to fill in the empty characters.
- For bilateral sites, the final character of the codes in the ICD-10 CM indicates laterality. If no bilateral code is provided and the condition is bilateral, separate codes for both the left and right side should be assigned. Unspecified codes should be used only when there is no other code option available.
- When the diagnosis code specifies laterality, regardless of which digit it is found in (i.e., 4th digit, 5th digit, or 6th digit):
 - Right is always 1
 - Left is always 2
 - Bilateral is always 3



APPENDIX 3. ALGORITHM FOR THE MANAGEMENT OF PATIENTS WITH ACUTE ANGLE-CLOSURE CRISIS



AACC = acute angle-closure crisis; ICE = iridocorneal endothelial; IOP = intraocular pressure; NVI = neovascularization of the iris; PAC = primary angle closure

* Indicated for extensive synechial closure or optic nerve damage.



APPENDIX 4. LITERATURE SEARCHES FOR THIS PPP

Literature searches of the PubMed and Cochrane databases were conducted in June 2014; the search strategies were as follows. Specific limited update searches were conducted after June 2014.

PubMed Searches

Lensectomy/cataract surgery & angle closure (4/29/09 – 6/11/14)

("Cataract Extraction"[Mesh] OR "cataract surgery" OR "cataract surgical" OR lensectomy) AND ("Glaucoma, Angle-Closure"[Mesh] OR "angle closure") AND ((2009/4/29[EDat]:3000[EDat]) AND (English[lang])): 137 references as of 6/11/14.

Laser iridotomy & cataract (4/22/09 – 6/11/14)

("Cataract"[Mesh] OR cataract*) AND "laser iridotomy" AND ((English[lang])) AND (2009/04/22[edat]:3000[edat]): 29 references as of 6/11/14; 28 imported; 1 duplicate.

Occlusion of iridotomy (4/22/09 – 6/11/14)

("Lasers"[Mesh] OR "Laser Therapy"[Mesh] OR "Lasers, Solid-State"[Mesh] OR laser OR lasers OR laser's OR YAG) AND iridotomy AND occlusion AND ((English[lang])) AND (2009/04/22[edat]:3000[edat]): 5 references as of 6/11/14.

Primary angle closure update (4/22/09 – 6/11/14)

"Glaucoma, Angle-Closure"[Mesh] AND (Humans[Mesh]) AND ((2009/04/22[EDat]:3000[EDat]) AND (English[lang])): 592 references as of 6/11/14.

Cochrane Searches

Lensectomy/cataract surgery & angle closure (4/2009 – 6/2014)

("Cataract Extraction"[Mesh] OR "cataract surgery" OR "cataract surgical" OR lensectomy) AND ("Glaucoma, Angle-Closure"[Mesh] OR "angle closure"): 1 result in Database of Abstracts of Reviews of Effectiveness as of 6/18/14.

Laser iridotomy & cataract (4/2009 – 6/2014)

("Cataract"[Mesh] OR cataract*) AND "laser iridotomy": 3 results in Cochrane Central Register of Controlled Trials as of 6/18/14.

Occlusion of iridotomy (4/2009 – 6/2014)

("Lasers"[Mesh] OR "Laser Therapy"[Mesh] OR "Lasers, Solid-State"[Mesh] OR laser* OR YAG) AND iridotomy AND occlu*: 1 result in Cochrane Central Register of Controlled Trials as of 6/19/14.

Primary angle closure update (4/2009 – 6/2014)

"Glaucoma, Angle-Closure"[Mesh] OR "angle closure glaucoma" OR "primary angle closure": 4 results in Cochrane Database of Systematic Reviews as of 6/19/14.



SUGGESTED REFERENCE TEXTS

- ◆ Allingham RR, Damji KF, Freedman S, Moroi SE, Rhee D, Shields MB, eds. Shields' Textbook of Glaucoma. 6th ed. Philadelphia, PA: Lippincott Williams & Wilkins; 2010.
- ◆ Alward WLM. www.gonioscopy.org. Accessed May 29, 2015.
- ◆ Heijl A, Traverso CE, eds. Terminology and Guidelines for Glaucoma. European Glaucoma Society. 4th ed. Savona, Italy: PubliComm; 2014. Available at: www.eugs.org/eng/EGS_guidelines4.asp. Accessed May 29, 2015.
- ◆ Kahook M, Shuman JS, eds. Chandler and Grant's Glaucoma. 5th ed. Thorofare, NJ: SLACK Inc.; 2013.
- ◆ Stamper RL, Lieberman MF, Drake MV. Becker-Shaffer's Diagnosis and Therapy of the Glaucomas. 8th ed. Philadelphia, PA: Mosby Elsevier; 2009.
- ◆ Tasman W, Jaeger EA, eds. Duane's Ophthalmology on DVD-ROM, 2013 ed. Philadelphia, PA: Lippincott Williams & Wilkins; 2012.
- ◆ Weinreb RN, Friedman DS, eds. Angle Closure and Angle-Closure Glaucoma. World Glaucoma Association Consensus Series - 3. The Netherlands: Kugler Publications; 2006.



RELATED ACADEMY MATERIALS

Basic and Clinical Science Course

Glaucoma (Section 10, 2015–2016)

Ophthalmic Technology Assessment – Free downloads available at www.aaojournal.org/content/OphthalmicTechnologyAssessment.

Evaluation of the Anterior Chamber Angle in Glaucoma (2013)

Patient Education

Glaucoma Brochure (2014) (also available in Spanish)

Glaucoma Patient Education Video Collection (2015)

Laser Iridotomy Brochure (2014)

Preferred Practice Pattern® Guidelines – Free downloads available at www.aao.org/ppp.

Comprehensive Adult Medical Eye Evaluation (2015)

Primary Open-Angle Glaucoma (2015)

Primary Open-Angle Glaucoma Suspect (2015)

Vision Rehabilitation for Adults (2013)

To order any of these products, except for the free materials, please contact the Academy's Customer Service at 866.561.8558 (U.S. only) or 415.561.8540 or www.aao.org/store.



REFERENCES

1. Scottish Intercollegiate Guidelines Network. Annex B: key to evidence statements and grades of recommendations. In: SIGN 50: A Guideline Developer's Handbook. 2008 edition, revised 2011. Edinburgh, Scotland: Scottish Intercollegiate Guidelines Network. Available at: www.sign.ac.uk/guidelines/fulltext/50/index.html. Accessed June 26, 2015.
2. Guyatt GH, Oxman AD, Vist GE, et al. GRADE: an emerging consensus on rating quality of evidence and strength of recommendations. *BMJ* 2008;336:924-6.
3. GRADE Working Group. Organizations that have endorsed or that are using GRADE. Available at: www.gradeworkinggroup.org/society/index.htm. Accessed May 29, 2015.
4. Anderson DR, Jin JC, Wright MM. The physiologic characteristics of relative pupillary block. *Am J Ophthalmol* 1991;111:344-50.
5. Tiedeman JS. A physical analysis of the factors that determine the contour of the iris. *Am J Ophthalmol* 1991;111:338-43.
6. Jin JC, Anderson DR. The effect of iridotomy on iris contour. *Am J Ophthalmol* 1990;110:260-3.
7. Seah SK, Foster PJ, Chew PT, et al. Incidence of acute primary angle-closure glaucoma in Singapore. An island-wide survey. *Arch Ophthalmol* 1997;115:1436-40.
8. Friedman DS, Gazzard G, Foster P, et al. Ultrasonographic biomicroscopy, Scheimpflug photography, and novel provocative tests in contralateral eyes of Chinese patients initially seen with acute angle closure. *Arch Ophthalmol* 2003;121:633-42.
9. Weinreb RN, Friedman DS, eds. Angle Closure and Angle Closure Glaucoma: Reports and Consensus Statements of the 3rd Global AIGS Consensus Meeting on Angle Closure Glaucoma. The Netherlands: Kugler Publications; 2006.
10. Leung CK, Cheung CY, Li H, et al. Dynamic analysis of dark-light changes of the anterior chamber angle with anterior segment OCT. *Invest Ophthalmol Vis Sci* 2007;48:4116-22.
11. Thomas R, Parikh R, Muliyl J, Kumar RS. Five-year risk of progression of primary angle closure to primary angle closure glaucoma: a population-based study. *Acta Ophthalmol Scand* 2003;81:480-5.
12. Thomas R, George R, Parikh R, et al. Five year risk of progression of primary angle closure suspects to primary angle closure: a population based study. *Br J Ophthalmol* 2003;87:450-4.
13. Hamanaka T, Kasahara K, Takemura T. Histopathology of the trabecular meshwork and Schlemm's canal in primary angle-closure glaucoma. *Invest Ophthalmol Vis Sci* 2011;52:8849-61.
14. American Academy of Ophthalmology Glaucoma Panel. Preferred Practice Pattern® Guidelines. Primary Open-Angle Glaucoma. San Francisco, CA: American Academy of Ophthalmology, 2015. Available at: www.aao.org/ppp.
15. Quigley HA. Long-term follow-up of laser iridotomy. *Ophthalmology* 1981;88:218-24.
16. He M, Friedman DS, Ge J, et al. Laser peripheral iridotomy in primary angle-closure suspects: biometric and gonioscopic outcomes: the Liwan Eye Study. *Ophthalmology* 2007;114:494-500.
17. He M, Friedman DS, Ge J, et al. Laser peripheral iridotomy in eyes with narrow drainage angles: ultrasound biomicroscopy outcomes. The Liwan Eye Study. *Ophthalmology* 2007;114:1513-9.
18. Kumar RS, Tantisevi V, Wong MH, et al. Plateau iris in Asian subjects with primary angle closure glaucoma. *Arch Ophthalmol* 2009;127:1269-72.
19. Kumar G, Bali SJ, Panda A, et al. Prevalence of plateau iris configuration in primary angle closure glaucoma using ultrasound biomicroscopy in the Indian population. *Indian J Ophthalmol* 2012;60:175-8.
20. Van Rens GH, Arkell SM, Charlton W, Doesburg W. Primary angle-closure glaucoma among Alaskan Eskimos. *Doc Ophthalmol* 1988;70:265-76.
21. Arkell SM, Lightman DA, Sommer A, et al. The prevalence of glaucoma among Eskimos of northwest Alaska. *Arch Ophthalmol* 1987;105:482-5.
22. Bourne RR, Sorensen KE, Klauber A, et al. Glaucoma in East Greenlandic Inuit--a population survey in Ittoqqortoormiit (Scoresbysund). *Acta Ophthalmol Scand* 2001;79:462-7.
23. Congdon NG, Quigley HA, Hung PT, et al. Screening techniques for angle-closure glaucoma in rural Taiwan. *Acta Ophthalmol Scand* 1996;74:113-9.
24. He M, Foster PJ, Ge J, et al. Prevalence and clinical characteristics of glaucoma in adult Chinese: a population-based study in Liwan District, Guangzhou. *Invest Ophthalmol Vis Sci* 2006;47:2782-8.

25. Foster PJ, Baasanhu J, Alsbirk PH, et al. Glaucoma in Mongolia. A population-based survey in Hovsgol province, northern Mongolia. *Arch Ophthalmol* 1996;114:1235-41.
26. Xu L, Zhang L, Xia CR, et al. The prevalence and its effective factors of primary angle-closure glaucoma in defined populations of rural and urban in Beijing [in Chinese]. *Zhonghua Yan Ke Za Zhi* 2005;41:8-14.
27. Foster PJ, Oen FT, Machin D, et al. The prevalence of glaucoma in Chinese residents of Singapore: a cross-sectional population survey of the Tanjong Pagar district. *Arch Ophthalmol* 2000;118:1105-11.
28. Casson RJ, Newland HS, Muecke J, et al. Prevalence of glaucoma in rural Myanmar: the Meiktila Eye Study. *Br J Ophthalmol* 2007;91:710-4.
29. Salmon JF, Mermoud A, Ivey A, et al. The prevalence of primary angle closure glaucoma and open angle glaucoma in Mamre, western Cape, South Africa. *Arch Ophthalmol* 1993;111:1263-9.
30. Dandona L, Dandona R, Mandal P, et al. Angle-closure glaucoma in an urban population in southern India. The Andhra Pradesh eye disease study. *Ophthalmology* 2000;107:1710-6.
31. Bourne RR, Sukudom P, Foster PJ, et al. Prevalence of glaucoma in Thailand: a population based survey in Rom Klao District, Bangkok. *Br J Ophthalmol* 2003;87:1069-74.
32. Vijaya L, George R, Arvind H, et al. Prevalence of angle-closure disease in a rural southern Indian population. *Arch Ophthalmol* 2006;124:403-9.
33. Ramakrishnan R, Nirmalan PK, Krishnadas R, et al. Glaucoma in a rural population of southern India: the Aravind comprehensive eye survey. *Ophthalmology* 2003;110:1484-90.
34. Rahman MM, Rahman N, Foster PJ, et al. The prevalence of glaucoma in Bangladesh: a population based survey in Dhaka division. *Br J Ophthalmol* 2004;88:1493-7.
35. Shiose Y, Kitazawa Y, Tsukahara S, et al. Epidemiology of glaucoma in Japan--a nationwide glaucoma survey. *Jpn J Ophthalmol* 1991;35:133-55.
36. Yamamoto T, Iwase A, Araie M, et al. The Tajimi Study report 2: prevalence of primary angle closure and secondary glaucoma in a Japanese population. *Ophthalmology* 2005;112:1661-9.
37. Tielsch JM, Katz J, Singh K, et al. A population-based evaluation of glaucoma screening: the Baltimore Eye Survey. *Am J Epidemiol* 1991;134:1102-10.
38. Buhrmann RR, Quigley HA, Barron Y, et al. Prevalence of glaucoma in a rural East African population. *Invest Ophthalmol Vis Sci* 2000;41:40-8.
39. Rotchford AP, Kirwan JF, Muller MA, et al. Temba glaucoma study: a population-based cross-sectional survey in urban South Africa. *Ophthalmology* 2003;110:376-82.
40. Bonomi L, Marchini G, Marraffa M, et al. Prevalence of glaucoma and intraocular pressure distribution in a defined population. The Egna-Neumarkt Study. *Ophthalmology* 1998;105:209-15.
41. Mitchell P, Smith W, Attebo K, Healey PR. Prevalence of open-angle glaucoma in Australia. The Blue Mountains Eye Study. *Ophthalmology* 1996;103:1661-9.
42. Banks JL, Perkins ES, Tsoulas S, Wright JE. Bedford glaucoma survey. *Br Med J* 1968;1:791-6.
43. Coffey M, Reidy A, Wormald R, et al. Prevalence of glaucoma in the west of Ireland. *Br J Ophthalmol* 1993;77:17-21.
44. Hollows FC, Graham PA. Intra-ocular pressure, glaucoma, and glaucoma suspects in a defined population. *Br J Ophthalmol* 1966;50:570-86.
45. Wensor MD, McCarty CA, Stanislavsky YL, et al. The prevalence of glaucoma in the Melbourne Visual Impairment Project. *Ophthalmology* 1998;105:733-9.
46. Klein BE, Klein R, Sponsel WE, et al. Prevalence of glaucoma. The Beaver Dam Eye Study. *Ophthalmology* 1992;99:1499-504.
47. Dielemans I, Vingerling JR, Wolfs RC, et al. The prevalence of primary open-angle glaucoma in a population-based study in The Netherlands: the Rotterdam Study. *Ophthalmology* 1994;101:1851-5.
48. Bengtsson B. The prevalence of glaucoma. *Br J Ophthalmol* 1981;65:46-9.
49. Foster PJ, Johnson GJ. Glaucoma in China: how big is the problem? *Br J Ophthalmol* 2001;85:1277-82.
50. Quigley HA, Broman AT. The number of people with glaucoma worldwide in 2010 and 2020. *Br J Ophthalmol* 2006;90:262-7.
51. Tham YC, Li X, Wong TY, et al. Global prevalence of glaucoma and projections of glaucoma burden through 2040: a systematic review and meta-analysis. *Ophthalmology* 2014;121:2081-90.
52. Quigley HA, West SK, Rodriguez J, et al. The prevalence of glaucoma in a population-based study of Hispanic subjects: Proyecto VER. *Arch Ophthalmol* 2001;119:1819-26.

Primary Angle Closure PPP: References

53. Leighton DA. Survey of the first-degree relatives of glaucoma patients. *Trans Ophthalmol Soc U K* 1976;96:28-32.
54. Perkins ES. Family studies in glaucoma. *Br J Ophthalmol* 1974;58:529-35.
55. Wolfs RC, Grobbee DE, Hofman A, de Jong PT. Risk of acute angle-closure glaucoma after diagnostic mydriasis in nonselected subjects: the Rotterdam Study. *Invest Ophthalmol Vis Sci* 1997;38:2683-7.
56. Stein JD, Kim DS, Niziol LM, et al. Differences in rates of glaucoma among Asian Americans and other racial groups, and among various Asian ethnic groups. *Ophthalmology* 2011;118:1031-7.
57. Congdon N, Wang F, Tielsch JM. Issues in the epidemiology and population-based screening of primary angle-closure glaucoma. *Surv Ophthalmol* 1992;36:411-23.
58. Nguyen N, Mora JS, Gaffney MM, et al. A high prevalence of occludable angles in a Vietnamese population. *Ophthalmology* 1996;103:1426-31.
59. Lai JS, Liu DT, Tham CC, et al. Epidemiology of acute primary angle-closure glaucoma in the Hong Kong Chinese population: prospective study. *Hong Kong Med J* 2001;7:118-23.
60. Van Herick W, Shaffer RN, Schwartz A. Estimation of width of angle of anterior chamber. Incidence and significance of the narrow angle. *Am J Ophthalmol* 1969;68:626-9.
61. Lowe RF. Aetiology of the anatomical basis for primary angle-closure glaucoma. Biometrical comparisons between normal eyes and eyes with primary angle-closure glaucoma. *Br J Ophthalmol* 1970;54:161-9.
62. Lavanya R, Foster PJ, Sakata LM, et al. Screening for narrow angles in the singapore population: evaluation of new noncontact screening methods. *Ophthalmology* 2008;115:1720-7, 7 e1-2.
63. Wojciechowski R, Congdon N, Anninger W, Teo Broman A. Age, gender, biometry, refractive error, and the anterior chamber angle among Alaskan Eskimos. *Ophthalmology* 2003;110:365-75.
64. Lee DA, Brubaker RF, Ilstrup DM. Anterior chamber dimensions in patients with narrow angles and angle-closure glaucoma. *Arch Ophthalmol* 1984;102:46-50.
65. Wishart PK, Batterbury M. Ocular hypertension: correlation of anterior chamber angle width and risk of progression to glaucoma. *Eye (Lond)* 1992;6 (Pt 3):248-56.
66. Lowe RF. Primary angle-closure glaucoma. Inheritance and environment. *Br J Ophthalmol* 1972;56:13-20.
67. Alsbirk PH. Anatomical risk factors in primary angle-closure glaucoma. A ten year follow up survey based on limbal and axial anterior chamber depths in a high risk population. *Int Ophthalmol* 1992;16:265-72.
68. Salmon JF, Swanevelde SA, Donald M. The dimensions of eyes with chronic angle-closure glaucoma. *J Glaucoma* 1994;3:237-43.
69. Alsbirk PH. Anterior chamber depth and primary angle-closure glaucoma. I. An epidemiologic study in Greenland Eskimos. *Acta Ophthalmol (Copenh)* 1975;53:89-104.
70. Kurita N, Mayama C, Tomidokoro A, et al. Potential of the pentacam in screening for primary angle closure and primary angle closure suspect. *J Glaucoma* 2009;18:506-12.
71. He M, Huang W, Zheng Y, et al. Anterior chamber depth in elderly Chinese: the Liwan Eye Study. *Ophthalmology* 2008;115:1286-90.
72. Xu L, Cao WF, Wang YX, et al. Anterior chamber depth and chamber angle and their associations with ocular and general parameters: the Beijing Eye Study. *Am J Ophthalmol* 2008;145:929-36.
73. Aung T, Nolan WP, Machin D, et al. Anterior chamber depth and the risk of primary angle closure in 2 East Asian populations. *Arch Ophthalmol* 2005;123:527-32.
74. Sihota R, Lakshmaiah NC, Agarwal HC, et al. Ocular parameters in the subgroups of angle closure glaucoma. *Clin Experiment Ophthalmol* 2000;28:253-8.
75. George R, Paul PG, Baskaran M, et al. Ocular biometry in occludable angles and angle closure glaucoma: a population based survey. *Br J Ophthalmol* 2003;87:399-402.
76. Lavanya R, Wong TY, Friedman DS, et al. Determinants of angle closure in older Singaporeans. *Arch Ophthalmol* 2008;126:686-91.
77. Aung T, Husain R, Gazzard G, et al. Changes in retinal nerve fiber layer thickness after acute primary angle closure. *Ophthalmology* 2004;111:1475-9.
78. Bain WE. The fellow eye in acute closed-angle glaucoma. *Br J Ophthalmol* 1957;41:193-9.
79. Lowe RF. Acute angle-closure glaucoma. The second eye: an analysis of 200 cases. *Br J Ophthalmol* 1962;46:641-50.

80. Liu X, Li M, Zhong YM, et al. Damage patterns of retinal nerve fiber layer in acute and chronic intraocular pressure elevation in primary angle closure glaucoma. *Int J Ophthalmol* 2010;3:152-7.
81. Aung T, Friedman DS, Chew PT, et al. Long-term outcomes in Asians after acute primary angle closure. *Ophthalmology* 2004;111:1464-9.
82. American Academy of Ophthalmology Preferred Practice Patterns Committee. Preferred Practice Pattern® Guidelines. Comprehensive Adult Medical Eye Evaluation. San Francisco, CA: American Academy of Ophthalmology; 2010. Available at: www.aao.org/ppp.
83. Centers for Medicare and Medicaid Services. Your Medicare coverage: glaucoma tests. Available at: www.medicare.gov/coverage/glaucoma-tests.html Accessed May 29, 2015.
84. Talluto D, Feith M, Allee S. Simultaneous angle closure in twins. *J Glaucoma* 1998;7:68-9.
85. Subak-Sharpe I, Low S, Nolan W, Foster PJ. Pharmacological and environmental factors in primary angle-closure glaucoma. *Br Med Bull* 2010;93:125-43.
86. Salmon JF. Predisposing factors for chronic angle-closure glaucoma. *Prog Retin Eye Res* 1999;18:121-32.
87. Amerasinghe N, Zhang J, Thalamuthu A, et al. The heritability and sibling risk of angle closure in Asians. *Ophthalmology* 2011;118:480-5.
88. Kong X, Chen Y, Chen X, Sun X. Influence of family history as a risk factor on primary angle closure and primary open angle glaucoma in a Chinese population. *Ophthalmic Epidemiol* 2011;18:226-32.
89. Panday VA, Rhee DJ. Review of sulfonamide-induced acute myopia and acute bilateral angle-closure glaucoma. *Compr Ophthalmol Update* 2007;8:271-6.
90. Fraunfelder FW, Fraunfelder FT, Keates EU. Topiramate-associated acute, bilateral, secondary angle-closure glaucoma. *Ophthalmology* 2004;111:109-11.
91. Li J, Tripathi RC, Tripathi BJ. Drug-induced ocular disorders. *Drug Saf* 2008;31:127-41.
92. Alonso RS, Ambrosio Junior R, Paranhos Junior A, et al. Glaucoma anterior chamber morphometry based on optical Scheimpflug images. *Arq Bras Oftalmol* 2010;73:497-500.
93. Henzan IM, Tomidokoro A, Uejo C, et al. Comparison of ultrasound biomicroscopic configurations among primary angle closure, its suspects, and nonoccludable angles: the Kumejima Study. *Am J Ophthalmol* 2011;151:1065-73.
94. Setälä K. Corneal endothelial cell density after an attack of acute glaucoma. *Acta Ophthalmol (Copenh)* 1979;57:1004-13.
95. Olsen T. The endothelial cell damage in acute glaucoma. On the corneal thickness response to intraocular pressure. *Acta Ophthalmol (Copenh)* 1980;58:257-66.
96. Bigar F, Witmer R. Corneal endothelial changes in primary acute angle-closure glaucoma. *Ophthalmology* 1982;89:596-9.
97. Markowitz SN, Morin JD. The endothelium in primary angle-closure glaucoma. *Am J Ophthalmol* 1984;98:103-4.
98. Aghaian E, Choe JE, Lin S, Stamper RL. Central corneal thickness of Caucasians, Chinese, Hispanics, Filipinos, African Americans, and Japanese in a glaucoma clinic. *Ophthalmology* 2004;111:2211-9.
99. Bhargava SK, Leighton DA, Phillips CI. Early angle-closure glaucoma. Distribution of iridotrabecular contact and response to pilocarpine. *Arch Ophthalmol* 1973;89:369-72.
100. Gazzard G, Foster PJ, Friedman DS, et al. Light to dark physiological variation in iridotrabecular angle width. *Br J Ophthalmol* 2004. Available at: http://bjo.bmj.com/content/suppl/2004/10/22/88.11.DC1/88_11_report.full. Accessed October 26, 2015.
101. Ishikawa H, Liebmann JM, Ritch R. Quantitative assessment of the anterior segment using ultrasound biomicroscopy. *Curr Opin Ophthalmol* 2000;11:133-9.
102. Kaushik S, Jain R, Pandav SS, Gupta A. Evaluation of the anterior chamber angle in Asian Indian eyes by ultrasound biomicroscopy and gonioscopy. *Indian J Ophthalmol* 2006;54:159-63.
103. Barkana Y, Dorairaj SK, Gerber Y, et al. Agreement between gonioscopy and ultrasound biomicroscopy in detecting iridotrabecular apposition. *Arch Ophthalmol* 2007;125:1331-5.
104. Nolan WP, See JL, Chew PT, et al. Detection of primary angle closure using anterior segment optical coherence tomography in Asian eyes. *Ophthalmology* 2007;114:33-9.
105. Friedman DS, He M. Anterior chamber angle assessment techniques. *Surv Ophthalmol* 2008;53:250-73.
106. Wong HT, Lim MC, Sakata LM, et al. High-definition optical coherence tomography imaging of the iridocorneal angle of the eye. *Arch Ophthalmol* 2009;127:256-60.
107. Baskaran M, Ho SW, Tun TA, et al. Assessment of circumferential angle-closure by the iris-trabecular contact index with swept-source optical coherence tomography. *Ophthalmology* 2013;120:2226-31.

**Primary Angle Closure PPP:
References**

108. Grewal DS, Brar GS, Jain R, Grewal SP. Comparison of Scheimpflug imaging and spectral domain anterior segment optical coherence tomography for detection of narrow anterior chamber angles. *Eye (Lond)* 2011;25:603-11.
109. Narayanaswamy A, Sakata LM, He MG, et al. Diagnostic performance of anterior chamber angle measurements for detecting eyes with narrow angles: an anterior segment OCT study. *Arch Ophthalmol* 2010;128:1321-7.
110. Nongpiur ME, Haaland BA, Friedman DS, et al. Classification algorithms based on anterior segment optical coherence tomography measurements for detection of angle closure. *Ophthalmology* 2013;120:48-54.
111. Qin B, Francis BA, Li Y, et al. Anterior chamber angle measurements using Schwalbe's line with high-resolution fourier-domain optical coherence tomography. *J Glaucoma* 2013;22:684-8.
112. Wilensky JT, Kaufman PL, Frohlichstein D, et al. Follow-up of angle-closure glaucoma suspects. *Am J Ophthalmol* 1993;115:338-46.
113. Blondeau P, Jaworski L, Turcotte PC. Follow-up of angle closure glaucoma suspects after laser iridotomy in Caucasians with normal intraocular pressure at diagnosis. *Can J Ophthalmol* 2011;46:247-53.
114. Ramani KK, Mani B, George RJ, Lingam V. Follow-up of primary angle closure suspects after laser peripheral iridotomy using ultrasound biomicroscopy and A-scan biometry for a period of 2 years. *J Glaucoma* 2009;18:521-7.
115. Saw SM, Gazzard G, Friedman DS. Interventions for angle-closure glaucoma: an evidence-based update. *Ophthalmology* 2003;110:1869-78.
116. Vera V, Naqi A, Belovay GW, et al. Dysphotopsia after temporal versus superior laser peripheral iridotomy: a prospective randomized paired eye trial. *Am J Ophthalmol* 2014;157:929-35.
117. American Academy of Ophthalmology. Policy Statement. Preoperative Assessment: Responsibilities of the Ophthalmologist. San Francisco, CA: American Academy of Ophthalmology; 2012. Available at: <http://one.aaao.org/guidelines-browse?filter=clinicalstatement>. Accessed May 29, 2015.
118. Robin AL, Pollack IP, deFaller JM. Effects of topical ALO 2145 (p-aminoclonidine hydrochloride) on the acute intraocular pressure rise after argon laser iridotomy. *Arch Ophthalmol* 1987;105:1208-11.
119. Rosenblatt MA, Luntz MH. Intraocular pressure rise after argon laser trabeculoplasty. *Br J Ophthalmol* 1987;71:772-5.
120. Barnes SD, Campagna JA, Dirks MS, Doe EA. Control of intraocular pressure elevations after argon laser trabeculoplasty: comparison of brimonidine 0.2% to apraclonidine 1.0%. *Ophthalmology* 1999;106:2033-7.
121. American Academy of Ophthalmology. Policy Statement. An Ophthalmologist's Duties Concerning Postoperative Care. San Francisco, CA: American Academy of Ophthalmology; 2012. Available at: <http://one.aaao.org/guidelines-browse?filter=clinicalstatement>. Accessed May 29, 2015.
122. Ritch R. Exfoliation syndrome and occludable angles. *Trans Am Ophthalmol Soc* 1994;92:845-944.
123. Gross FJ, Tingey D, Epstein DL. Increased prevalence of occludable angles and angle-closure glaucoma in patients with pseudoexfoliation. *Am J Ophthalmol* 1994;117:333-6.
124. Brusini P, Tosoni C, Miani P. Increased prevalence of occludable angles and angle-closure glaucoma in patients with pseudoexfoliation. *Am J Ophthalmol* 1994;118:540.
125. Franks WA, Miller MH, Hitchings RA, Jeffrey MN. Secondary angle closure in association with pseudoexfoliation of the lens capsule. *Acta Ophthalmol (Copenh)* 1990;68:350-2.
126. Campbell DG, Vela A. Modern goniosynechialysis for the treatment of synechial angle-closure glaucoma. *Ophthalmology* 1984;91:1052-60.
127. Shingleton BJ, Chang MA, Bellows AR, Thomas JV. Surgical goniosynechialysis for angle-closure glaucoma. *Ophthalmology* 1990;97:551-6.
128. Tanihara H, Nishiwaki K, Nagata M. Surgical results and complications of goniosynechialysis. *Graefes Arch Clin Exp Ophthalmol* 1992;30:309-13.
129. Wand M. Argon laser goniotomy for synechial angle closure. *Arch Ophthalmol* 1992;110:363-7.
130. Steuhl KP, Marahrens P, Frohn C, Frohn A. Intraocular pressure and anterior chamber depth before and after extracapsular cataract extraction with posterior chamber lens implantation. *Ophthalmic Surg* 1992;23:233-7.
131. Yang CH, Hung PT. Intraocular lens position and anterior chamber angle changes after cataract extraction in eyes with primary angle-closure glaucoma. *J Cataract Refract Surg* 1997;23:1109-13.

132. Hayashi K, Hayashi H, Nakao F, Hayashi F. Changes in anterior chamber angle width and depth after intraocular lens implantation in eyes with glaucoma. *Ophthalmology* 2000;107:698-703.
133. Tham CC, Lai JS, Lam DS. Changes in AC angle width and depth after IOL implantation in eyes with glaucoma. *Ophthalmology* 2001;108:428-9.
134. Greve EL. Primary angle closure glaucoma: extracapsular cataract extraction or filtering procedure? *Int Ophthalmol* 1988;12:157-62.
135. Keenan TD, Salmon JF, Yeates D, Goldacre M. Trends in rates of primary angle closure glaucoma and cataract surgery in England from 1968 to 2004. *J Glaucoma* 2009;18:201-5.
136. Wishart PK, Atkinson PL. Extracapsular cataract extraction and posterior chamber lens implantation in patients with primary chronic angle-closure glaucoma: effect on intraocular pressure control. *Eye* 1989;3 (Pt 6):706-12.
137. Gunning FP, Greve EL. Uncontrolled primary angle closure glaucoma: results of early intercapsular cataract extraction and posterior chamber lens implantation. *Int Ophthalmol* 1991;15:237-47.
138. Acton J, Salmon JF, Scholtz R. Extracapsular cataract extraction with posterior chamber lens implantation in primary angle-closure glaucoma. *J Cataract Refract Surg* 1997;23:930-4.
139. Gunning FP, Greve EL. Lens extraction for uncontrolled angle-closure glaucoma: long-term follow-up. *J Cataract Refract Surg* 1998;24:1347-56.
140. Roberts TV, Francis IC, Lertusumitkul S, et al. Primary phacoemulsification for uncontrolled angle-closure glaucoma. *J Cataract Refract Surg* 2000;26:1012-6.
141. Hayashi K, Hayashi H, Nakao F, Hayashi F. Effect of cataract surgery on intraocular pressure control in glaucoma patients. *J Cataract Refract Surg* 2001;27:1779-86.
142. Jacobi PC, Dietlein TS, Luke C, et al. Primary phacoemulsification and intraocular lens implantation for acute angle-closure glaucoma. *Ophthalmology* 2002;109:1597-603.
143. Khokar K, Pangtey M. Phacoemulsification in filtered chronic angle closure glaucoma eyes. *Clin Experiment Ophthalmol* 2002;30:256-60.
144. Ming Zhi Z, Lim AS, Yin Wong T. A pilot study of lens extraction in the management of acute primary angle-closure glaucoma. *Am J Ophthalmol* 2003;135:534-6.
145. Kubota T, Toguri I, Onizuka N, Matsuura T. Phacoemulsification and intraocular lens implantation for angle closure glaucoma after the relief of pupillary block. *Ophthalmologica* 2003;217:325-8.
146. Shams PN, Foster PJ. Clinical outcomes after lens extraction for visually significant cataract in eyes with primary angle closure. *J Glaucoma* 2012;21:545-50.
147. Lam DS, Leung DY, Tham CC, et al. Randomized trial of early phacoemulsification versus peripheral iridotomy to prevent intraocular pressure rise after acute primary angle closure. *Ophthalmology* 2008;115:1134-40.
148. Lai JS, Tham CC, Chua JK, et al. To compare argon laser peripheral iridoplasty (ALPI) against systemic medications in treatment of acute primary angle-closure: mid-term results. *Eye (Lond)* 2006;20:309-14.
149. Lam DS, Tham CC, Lai JS, Leung DY. Current approaches to the management of acute primary angle closure. *Curr Opin Ophthalmol* 2007;18:146-51.
150. Lam DS, Chua JK, Tham CC, Lai JS. Efficacy and safety of immediate anterior chamber paracentesis in the treatment of acute primary angle-closure glaucoma: a pilot study. *Ophthalmology* 2002;109:64-70.
151. Ritch R, Lowe RF. Angle-closure glaucoma: therapeutic overview. In: Ritch R, Shields MB, Krupin T, eds. *The Glaucomas*. St. Louis: CV Mosby Co; 1996:1521-31.
152. Choong YF, Irfan S, Menage MJ. Acute angle closure glaucoma: an evaluation of a protocol for acute treatment. *Eye (Lond)* 1999;13 (Pt 5):613-6.
153. Aung T, Oen F, Wong H-T, et al. Randomised controlled trial comparing the effect of brimonidine and timolol on visual field loss after acute primary angle closure. *Br J Ophthalmol* 2004;88:88-94.
154. Koyabashi H, Koyabashi K, Kiryu J, Kondo T. Pilocarpine induces an increase in the anterior chamber angular width in eyes with narrow angles. *Br J Ophthalmol* 1999;83:553-8.
155. Anderson DR. Corneal indentation to relieve acute angle-closure glaucoma. *Am J Ophthalmol* 1979;88:1091-3.
156. American Academy of Ophthalmology Committee on Ophthalmic Procedures Assessment. Laser peripheral iridotomy for pupillary-block glaucoma. *American Academy of Ophthalmology. Ophthalmology* 1994;101:1749-58.

**Primary Angle Closure PPP:
References**

157. Robin AL, Pollack IP. Argon laser peripheral iridotomies in the treatment of primary angle closure glaucoma. Long-term follow-up. *Arch Ophthalmol* 1982;100:919-23.
158. Ang GS, Wells AP. Changes in Caucasian eyes after laser peripheral iridotomy: an anterior segment optical coherence tomography study. *Clin Experiment Ophthalmol* 2010;38:778-85.
159. Athanasiadis Y, de Wit D, Patel A, Sharma A. Reply to Yip et al: The potential complications from intraocular surgery, though, are greater than those from LPI. *Eye (Lond)* 2011;25:254-5; author reply 255-6.
160. How AC, Baskaran M, Kumar RS, et al. Changes in anterior segment morphology after laser peripheral iridotomy: an anterior segment optical coherence tomography study. *Ophthalmology* 2012;119:1383-7.
161. Boey PY, Singhal S, Perera SA, Aung T. Conventional and emerging treatments in the management of acute primary angle closure. *Clin Ophthalmol* 2012;6:417-24.
162. Ritch R. Argon laser peripheral iridoplasty: an overview. *J Glaucoma* 1992;1:206-13.
163. Shin DH. Argon laser iris photocoagulation to relieve acute angle-closure glaucoma. *Am J Ophthalmol* 1982;93:348-50.
164. Ritch R. Argon laser treatment for medically unresponsive attacks of angle-closure glaucoma. *Am J Ophthalmol* 1982;94:197-204.
165. Lai JS, Tham CC, Lam DS. Limited argon laser peripheral iridoplasty as immediate treatment for an acute attack of primary angle closure glaucoma: a preliminary study. *Eye (Lond)* 1999;13 (Pt 1):26-30.
166. Lam DS, Lai JS, Tham CC. Immediate argon laser peripheral iridoplasty as treatment for acute attack of primary angle-closure glaucoma: a preliminary study. *Ophthalmology* 1998;105:2231-6.
167. Tham CC, Lai JS, Lam DS. Immediate argon laser peripheral iridoplasty for acute attack of PACG (addendum to previous report). *Ophthalmology* 1999;106:1042-3.
168. Lam DS, Lai JS, Tham CC, et al. Argon laser peripheral iridoplasty versus conventional systemic medical therapy in treatment of acute primary angle-closure glaucoma : a prospective, randomized, controlled trial. *Ophthalmology* 2002;109:1591-6.
169. Lai JS, Tham CC, Lam DS. The efficacy and safety of combined phacoemulsification, intraocular lens implantation, and limited goniosynechialysis, followed by diode laser peripheral iridoplasty, in the treatment of cataract and chronic angle-closure glaucoma. *J Glaucoma* 2001;10:309-15.
170. Yang X, Su W, Wang M, et al. Effect of anterior chamber paracentesis on initial treatment of acute angle closure. *Can J Ophthalmol* 2013;48:553-8.
171. Aung T, Tow SL, Yap EY, et al. Trabeculectomy for acute primary angle closure. *Ophthalmology* 2000;107:1298-302.
172. Chen YH, Lu DW, Cheng JH, et al. Trabeculectomy in patients with primary angle-closure glaucoma. *J Glaucoma* 2009;18:679-83.
173. Wishart PK, Atkinson PL. Extracapsular cataract extraction and posterior chamber lens implantation in patients with primary chronic angle-closure glaucoma: effect on intraocular pressure control. *Eye (Lond)* 1989;3 (Pt 6):706-12.
174. Harasymowycz PJ, Papamatheakis DG, Ahmed I, et al. Phacoemulsification and goniosynechialysis in the management of unresponsive primary angle closure. *J Glaucoma* 2005;14:186-9.
175. Matsumura M, Ido W, Shirakam Y, Zoizumi K. Treatment of primary closed angle glaucoma with cataract by lysis of peripheral anterior synechiae and intraocular lens implantation. *Jpn J Clin Ophthalmol* 1991;45:1567-9.
176. Teekhasaene C, Ritch R. Combined phacoemulsification and goniosynechialysis for uncontrolled chronic angle-closure glaucoma after acute angle-closure glaucoma. *Ophthalmology* 1999;106:669-74; discussion 674-5.
177. Tham CC, Kwong YY, Leung DY, et al. Phacoemulsification versus combined phacotrabeculectomy in medically uncontrolled chronic angle closure glaucoma with cataracts. *Ophthalmology* 2009;116:725-31.
178. Husain R, Gazzard G, Aung T, et al. Initial management of acute primary angle closure: a randomized trial comparing phacoemulsification with laser peripheral iridotomy. *Ophthalmology* 2012;119:2274-81.
179. Azuara-Blanco A, Burr JM, Cochran C, et al, Effectiveness in Angle-closure Glaucoma of Lens Extraction (EAGLE) Study Group. The effectiveness of early lens extraction with intraocular lens implantation for the treatment of primary angle-closure glaucoma (EAGLE): study protocol for a randomized controlled trial. *Trials* 2011;12:133.
180. Edwards RS. Behaviour of the fellow eye in acute angle-closure glaucoma. *Br J Ophthalmol* 1982;66:576-9.

181. Ang LP, Aung T, Chew PT. Acute primary angle closure in an Asian population: long-term outcome of the fellow eye after prophylactic laser peripheral iridotomy. *Ophthalmology* 2000;107:2092-6.
182. Snow JT. Value of prophylactic peripheral iridectomy on the second eye in angle-closure glaucoma. *Trans Ophthalmol Soc U K* 1977;97:189-91.
183. Ritch R, Tham CC, Lam DS. Long-term success of argon laser peripheral iridoplasty in the management of plateau iris syndrome. *Ophthalmology* 2004;111:104-8.
184. Ng WS, Ang GS, Azuara-Blanco A. Laser peripheral iridoplasty for angle-closure. *Cochrane Database of Syst Rev* 2012, Issue 2. Art. No.: CD006746. DOI: 10.1002/14651858.CD006746.pub3.
185. Department of Health & Human Services Centers for Medicare & Medicaid Services. Early refill edits on topical ophthalmic products [memorandum]. June 2, 2010. Available at: www.cms.gov/Medicare/Prescription-Drug-Coverage/PrescriptionDrugCovContra/Downloads/MemoEarlyRefillOph_060210.pdf. Accessed May 29, 2015.
186. American Academy of Ophthalmology Vision Rehabilitation Committee. Preferred Practice Pattern® Guidelines. Vision Rehabilitation. San Francisco, CA: American Academy of Ophthalmology, 2013. Available at: www.aao.org/ppp.
187. Varma R, Lee PP, Goldberg I, Kotak S. An assessment of the health and economic burdens of glaucoma. *Am J Ophthalmol* 2011;152:515-22.
188. Ramulu P. Glaucoma and disability: which tasks are affected, and at what stage of disease? *Curr Opin Ophthalmol* 2009;20:92-8.
189. Haymes SA, Leblanc RP, Nicolela MT, et al. Risk of falls and motor vehicle collisions in glaucoma. *Invest Ophthalmol Vis Sci* 2007;48:1149-55.
190. McKean-Cowdin R, Varma R, Wu J, et al. Severity of visual field loss and health-related quality of life. *Am J Ophthalmol* 2007;143:1013-23.
191. Rein DB, Zhang P, Wirth KE, et al. The economic burden of major adult visual disorders in the United States. *Arch Ophthalmol* 2006;124:1754-60.
192. Kymes SM, Plotzke MR, Li JZ, et al. The increased cost of medical services for people diagnosed with primary open-angle glaucoma: a decision analytic approach. *Am J Ophthalmol* 2010;150:74-81.
193. Lee PP, Walt JG, Doyle JJ, et al. A multicenter, retrospective pilot study of resource use and costs associated with severity of disease in glaucoma. *Arch Ophthalmol* 2006;124:12-9.
194. Lindblom B, Nordmann JP, Sellem E, et al. A multicentre, retrospective study of resource utilization and costs associated with glaucoma management in France and Sweden. *Acta Ophthalmol Scand* 2006;84:74-83.
195. Poulsen PB, Buchholz P, Walt JG, et al. Cost-analysis of glaucoma-related blindness in Europe. *International Congress Series* 2005;1292:262-6.
196. Thygesen J, Aagren M, Arnavielle S, et al. Late-stage, primary open-angle glaucoma in Europe: social and health care maintenance costs and quality of life of patients from 4 countries. *Curr Med Res Opin* 2008;24:1763-70.
197. Quigley HA, Cassard SD, Gower EW, et al. The cost of glaucoma care provided to Medicare beneficiaries from 2002 to 2009. *Ophthalmology* 2013;120:2249-57.
198. Sloan FA, Brown DS, Carlisle ES, et al. Monitoring visual status: why patients do or do not comply with practice guidelines. *Health Serv Res* 2004;39:1429-48.
199. Wang F, Javitt JC, Tielsch JM. Racial variations in treatment for glaucoma and cataract among Medicare recipients. *Ophthalmic Epidemiol* 1997;4:89-100.
200. Coleman AL, Yu F, Rowe S. Visual field testing in glaucoma Medicare beneficiaries before surgery. *Ophthalmology* 2005;112:401-6.
201. Devgan U, Yu F, Kim E, Coleman AL. Surgical undertreatment of glaucoma in black beneficiaries of medicare. *Arch Ophthalmol* 2000;118:253-6.
202. Stein JD, Talwar N, Laverne AM, et al. Racial disparities in the use of ancillary testing to evaluate individuals with open-angle glaucoma. *Arch Ophthalmol* 2012;130:1579-88.



P.O. Box 7424
San Francisco,
California 94120-7424
415.561.8500

Primary Angle
Closure 2015